

Emergency Radiology

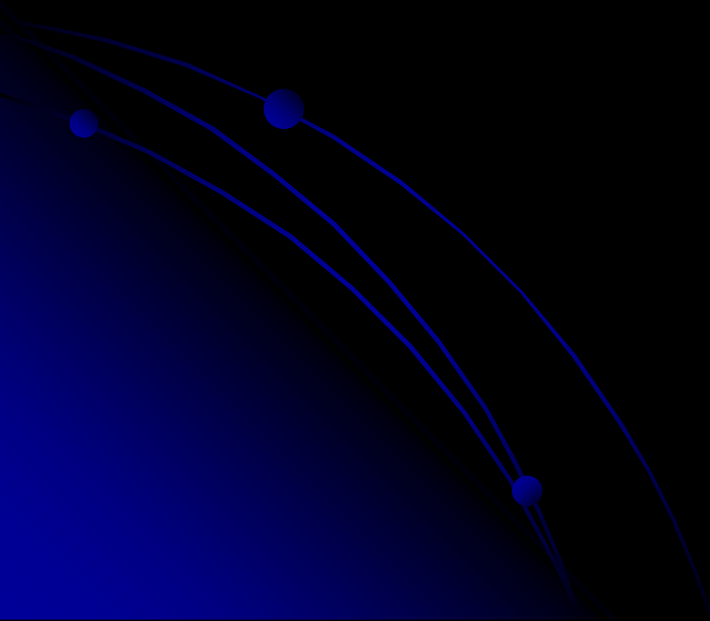
Eric Patrick, M.D.



**TRAUMATIC
VS.
NONTRAUMATIC
EMERGENCIES**

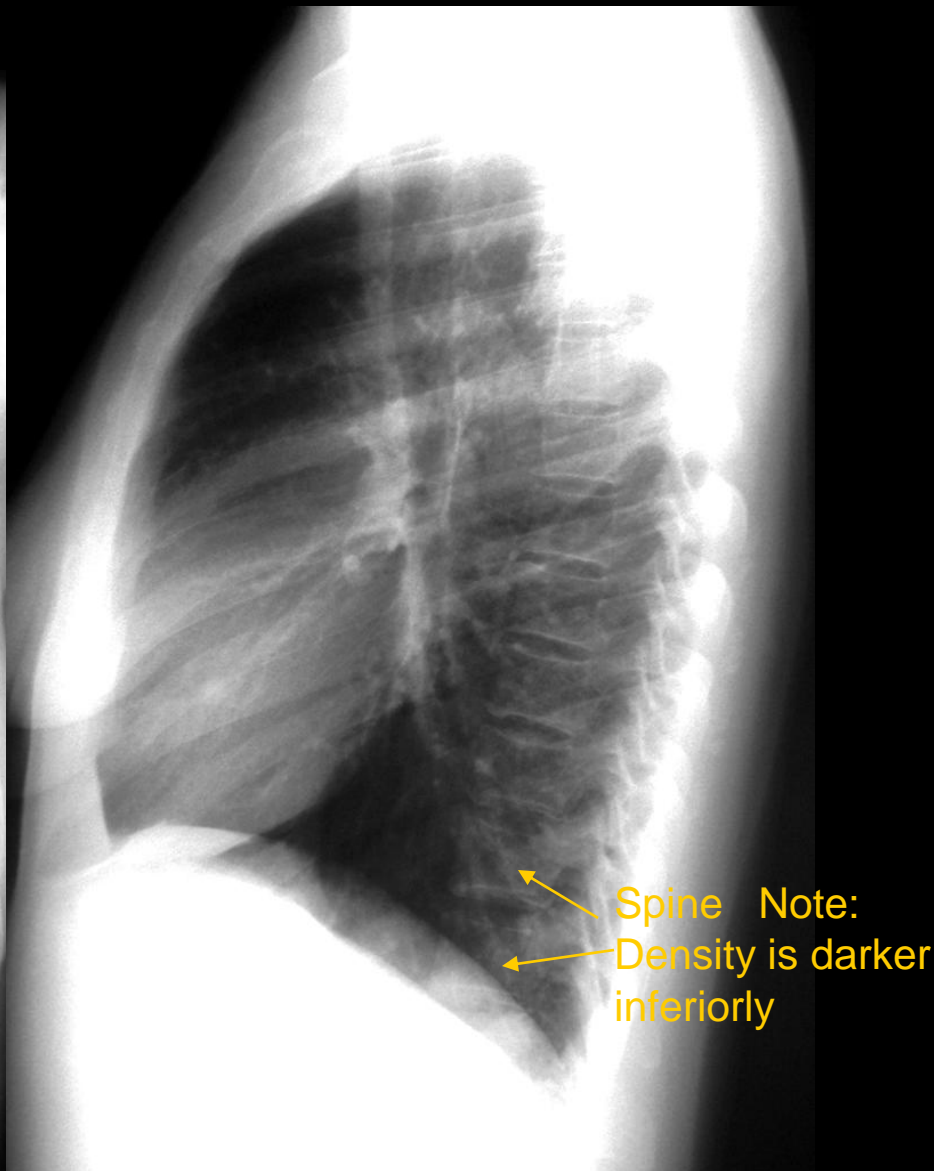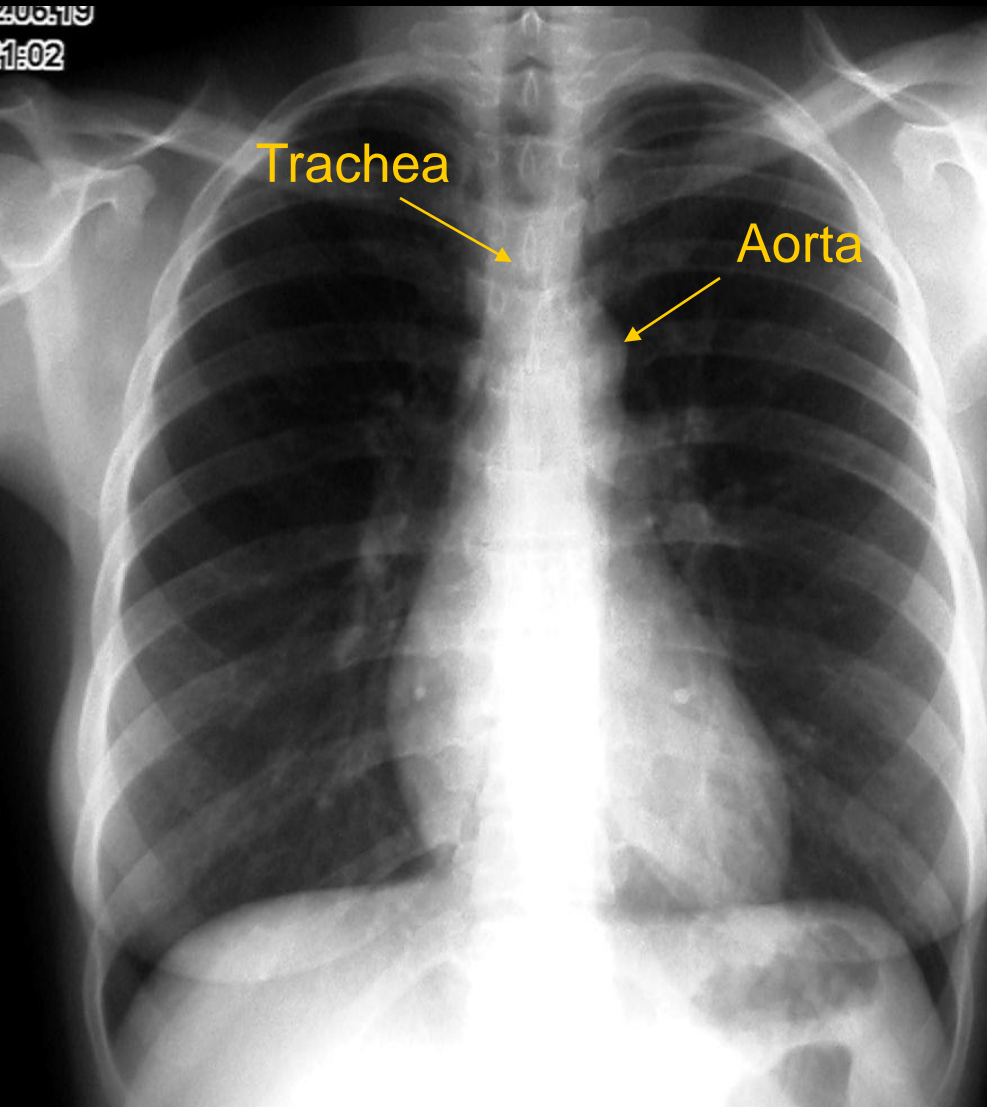


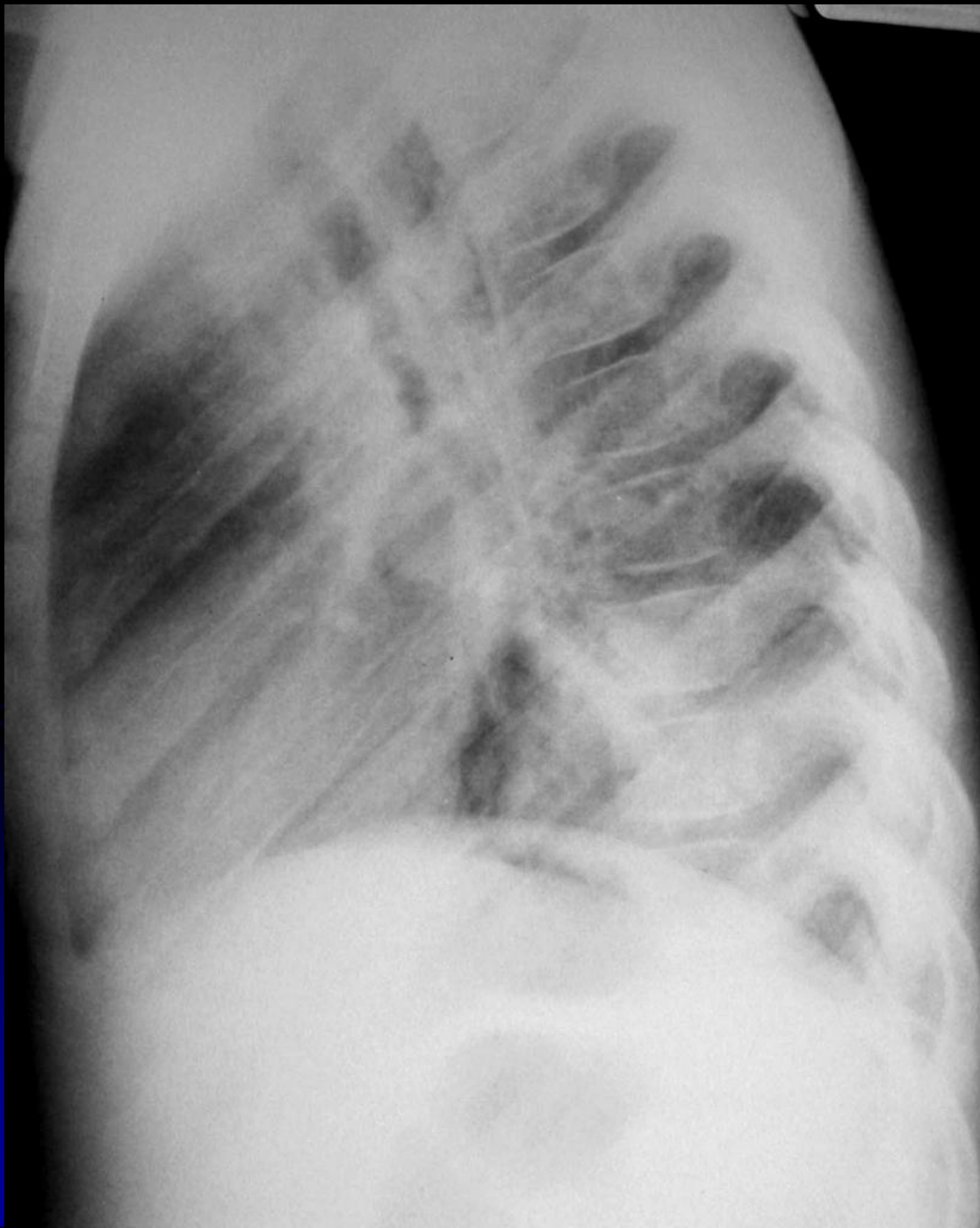
CHEST



Normal

400519
1:02



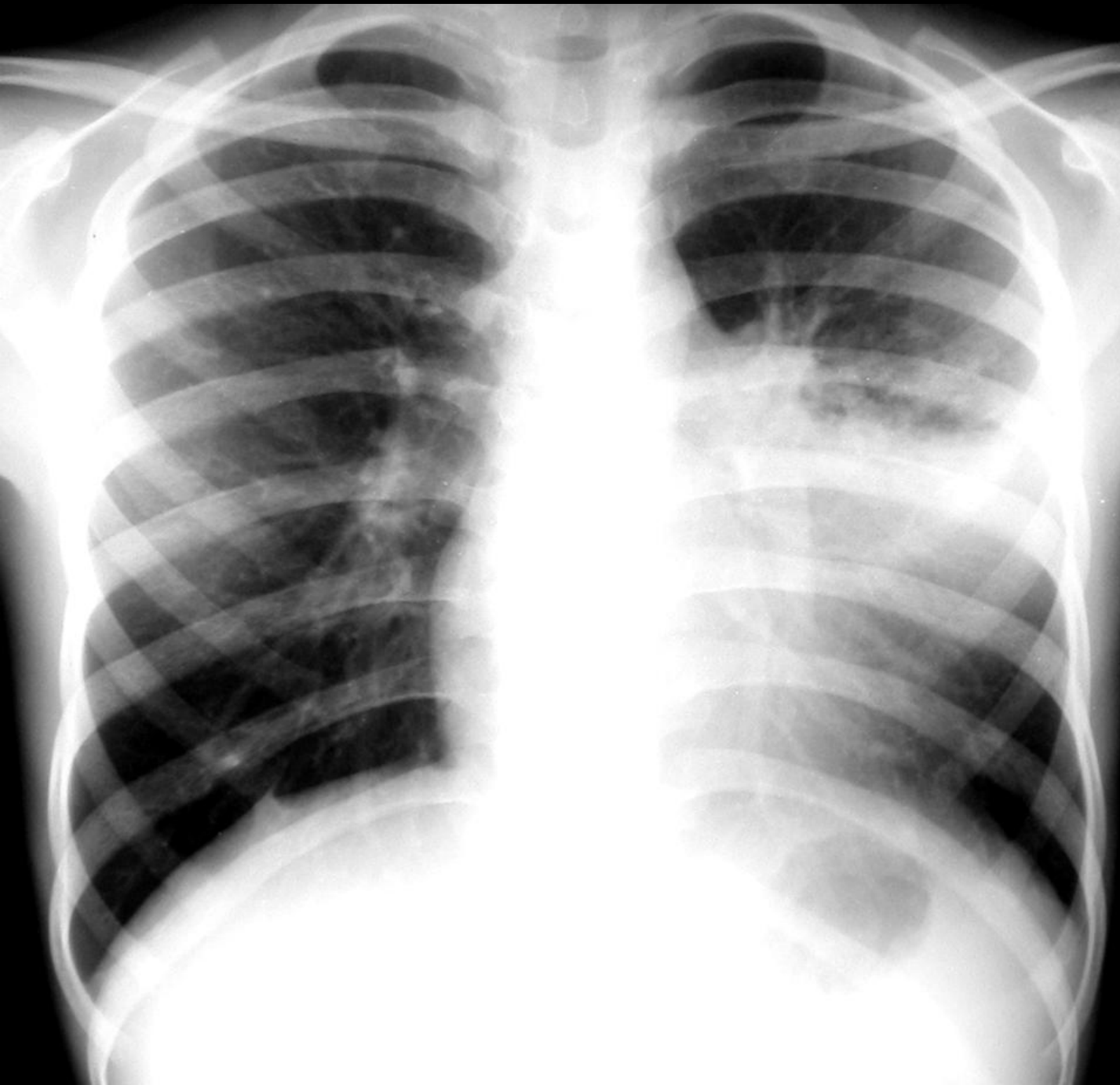


History: FEVER

“SPINE SIGN”

DIAGNOSIS?

-Pneumonia



Hx: FEVER

**Lingula
Pneumonia**

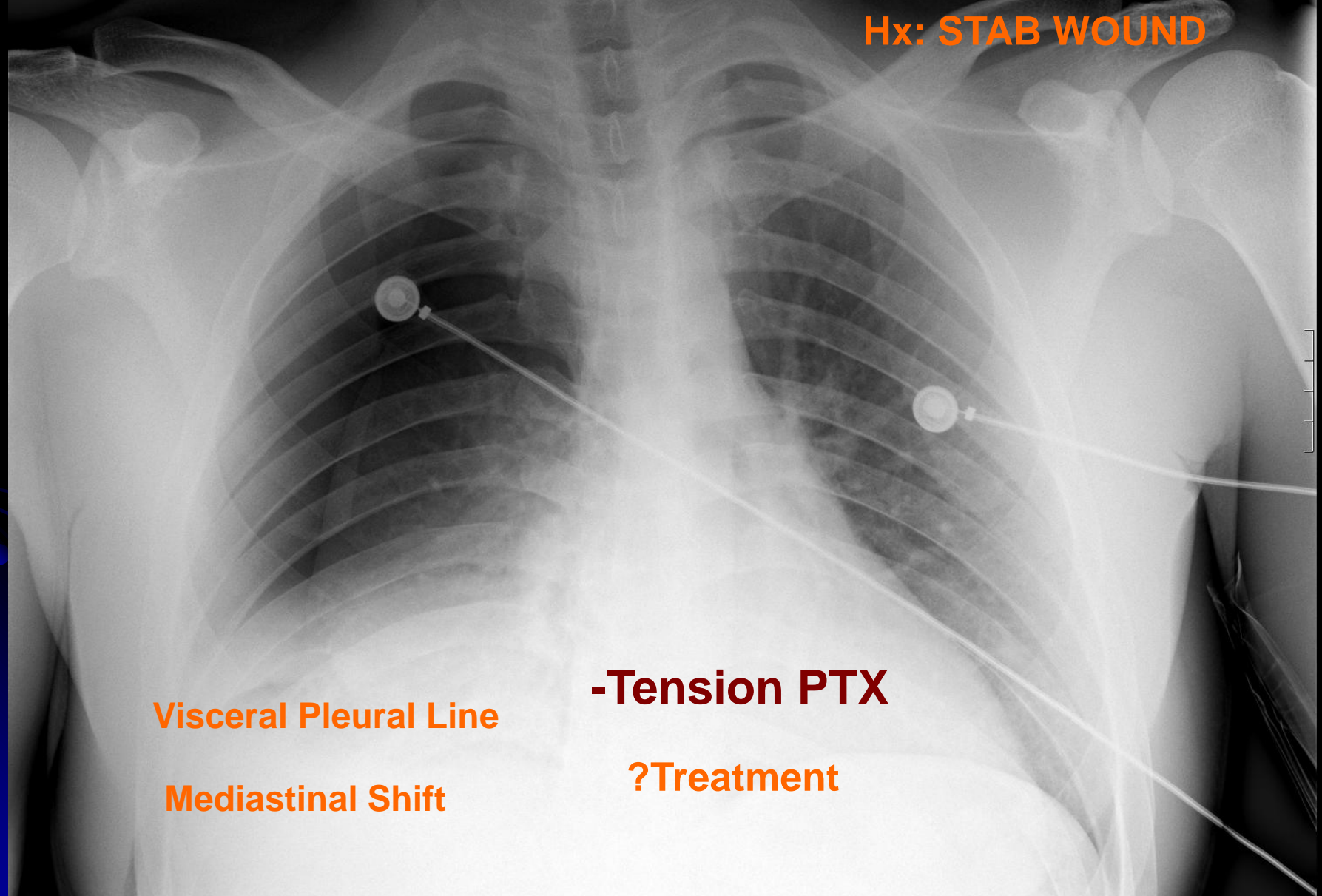
SeNo:1001
ImNo:1001

Portable

UPRIGHT

x 0.352

Hx: STAB WOUND



Visceral Pleural Line

Mediastinal Shift

-Tension PTX

?Treatment

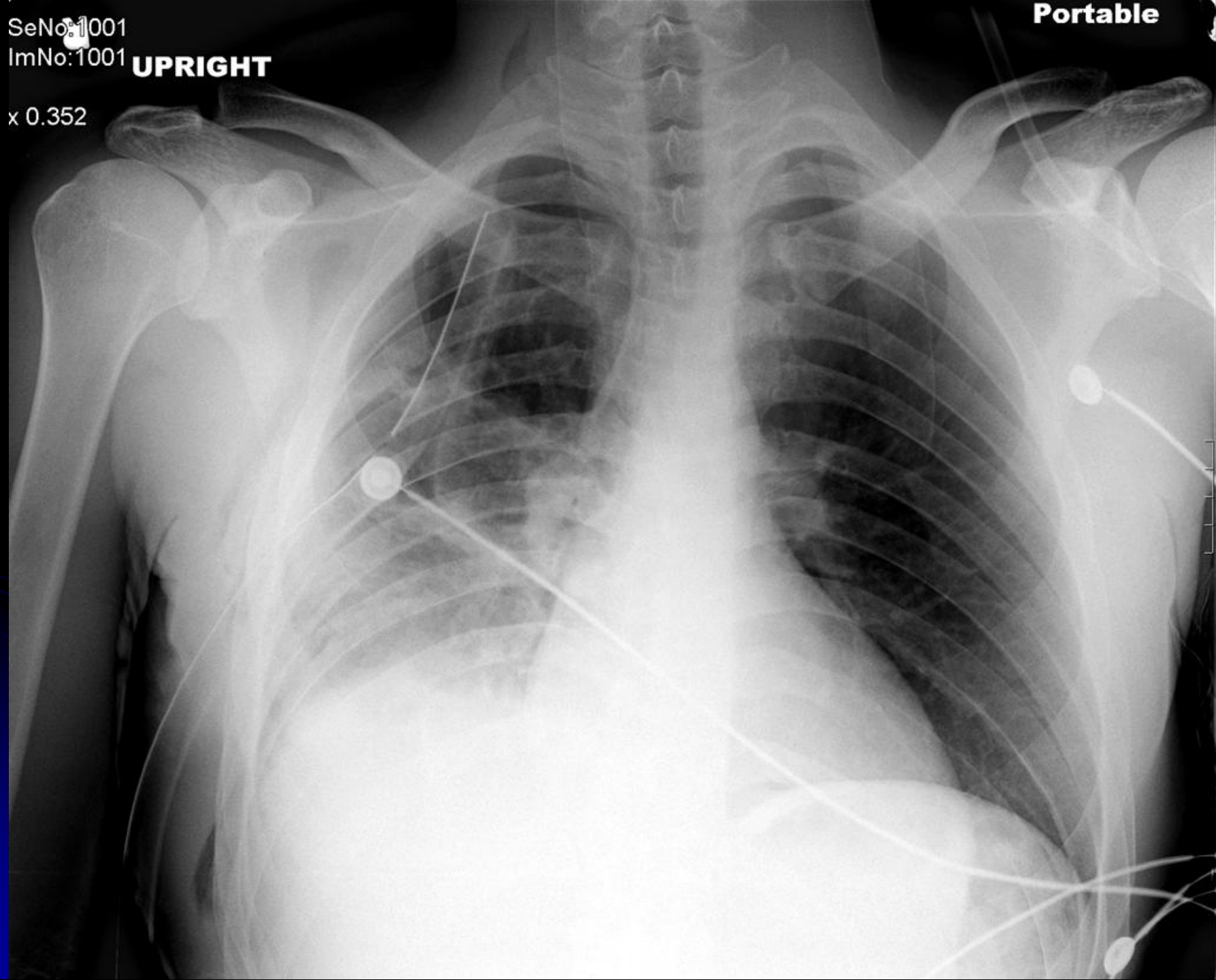
SeNo:1001

ImNo:1001

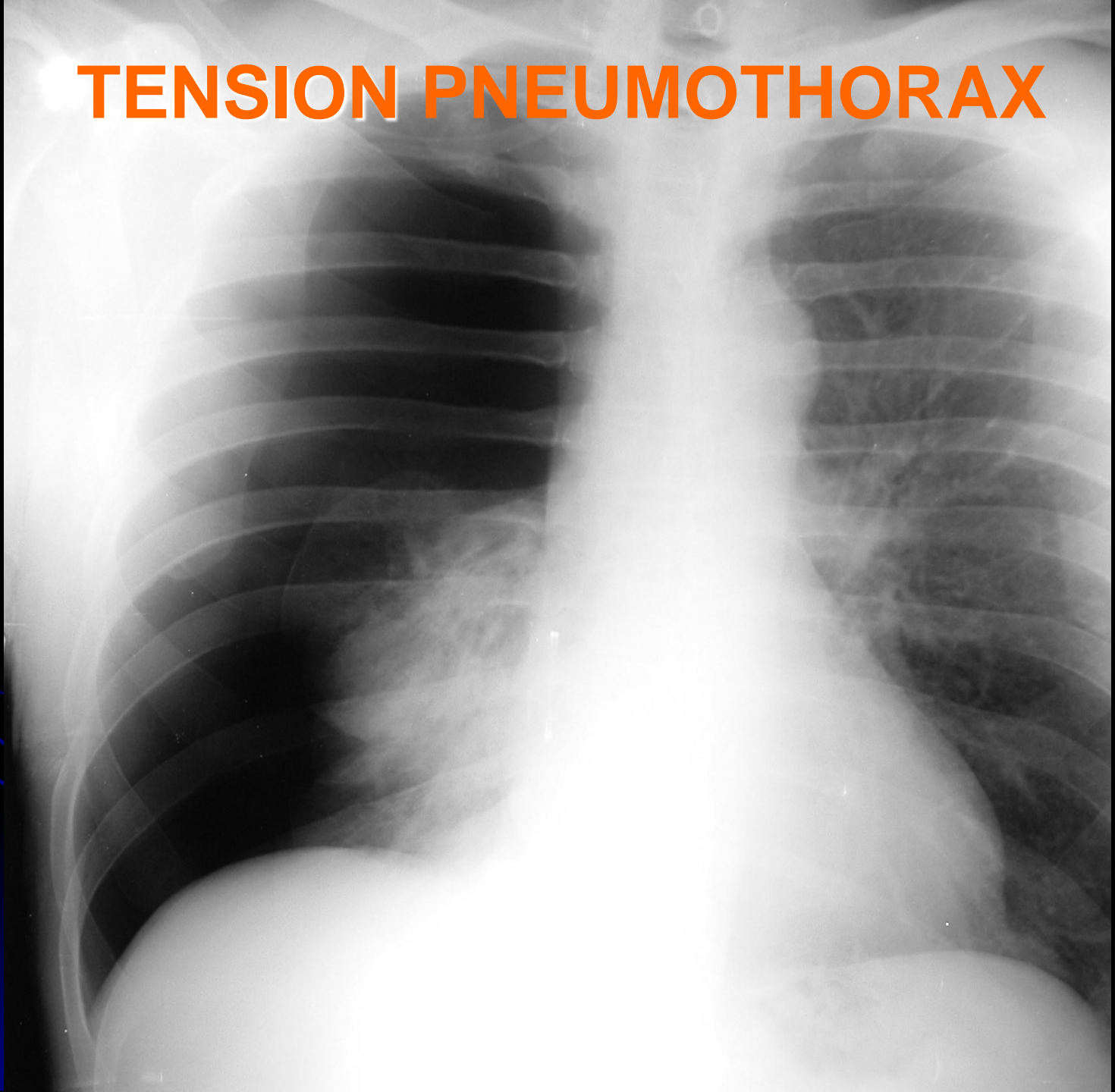UPRIGHT

Portable

x 0.352



TENSION PNEUMOTHORAX



CHEST REVIEW

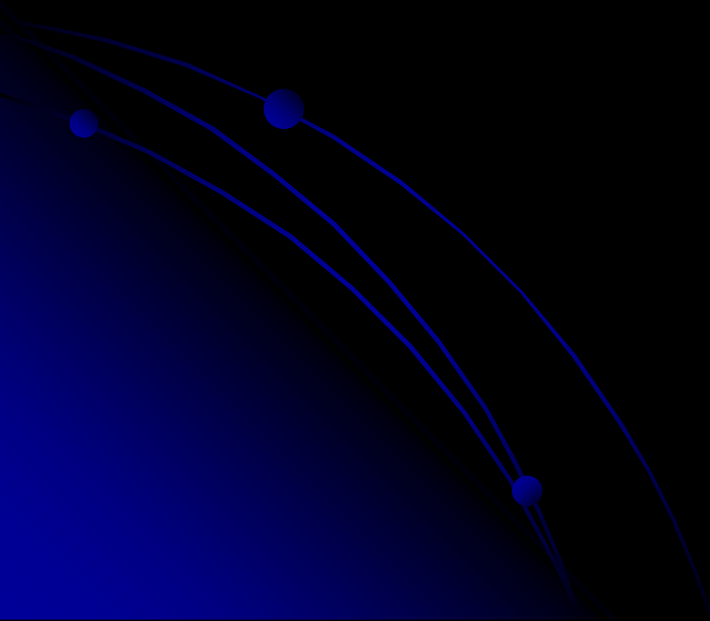
- Normal CXR

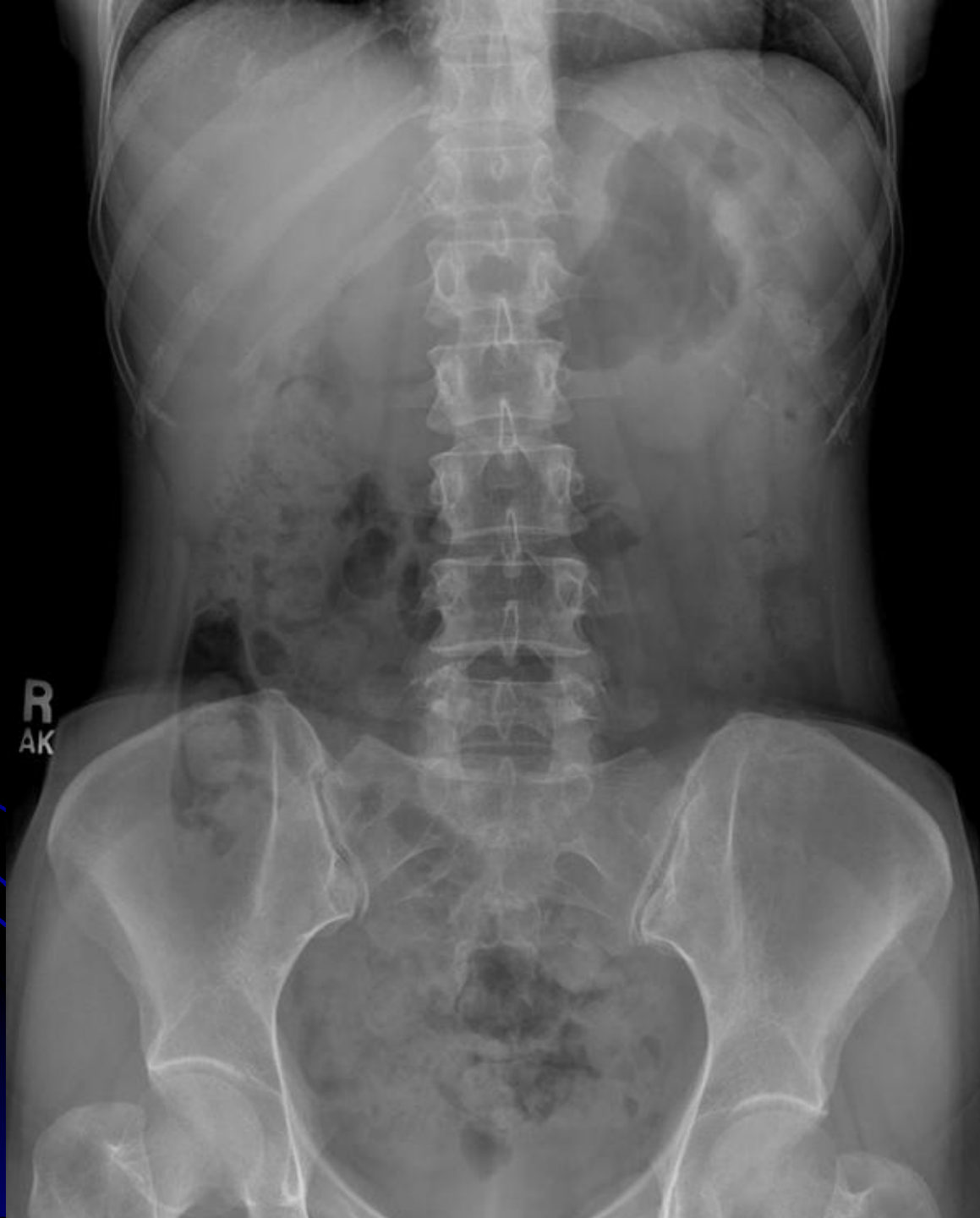
- Pneumonia

- Pneumothorax (do not miss) and tx



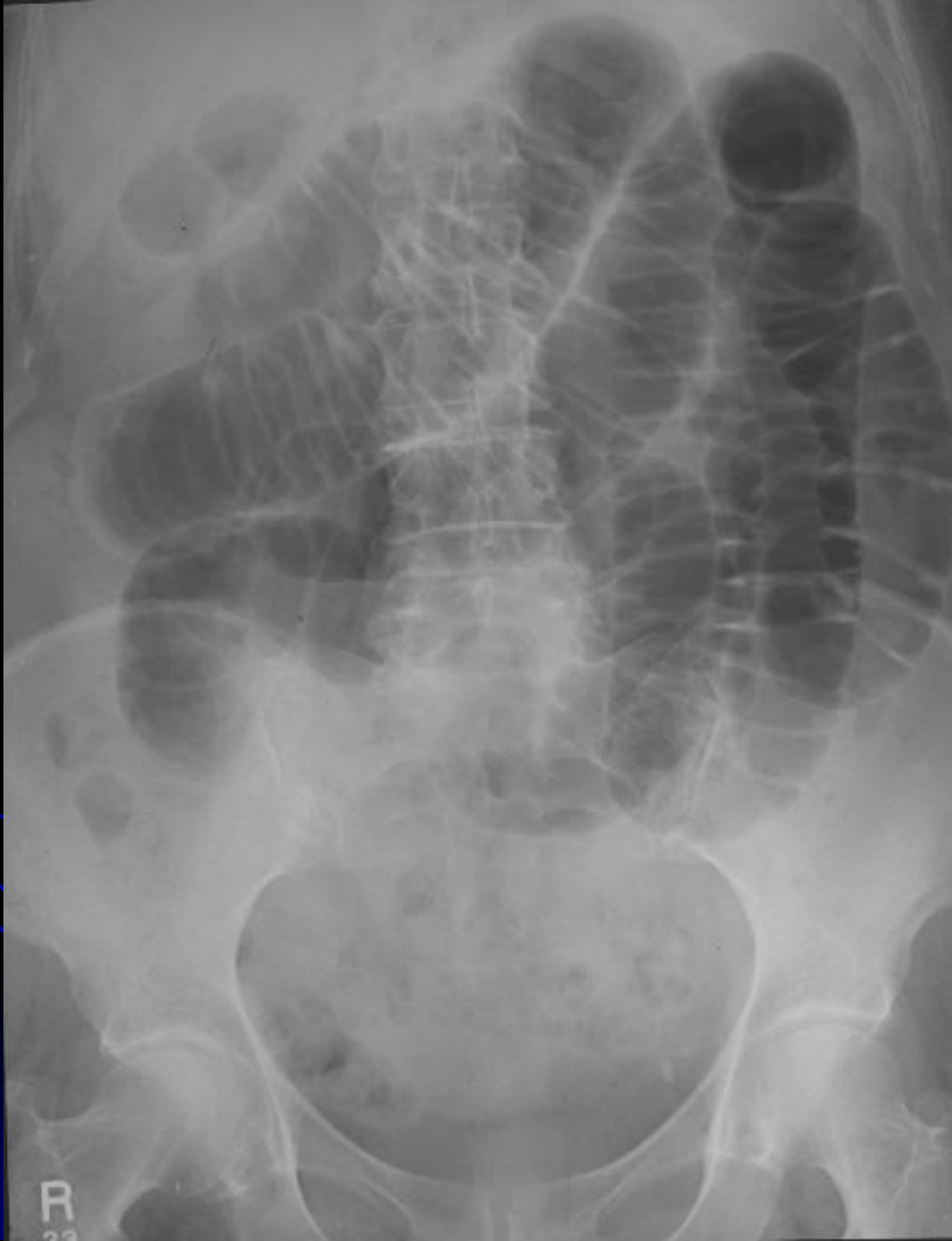ABDOMEN





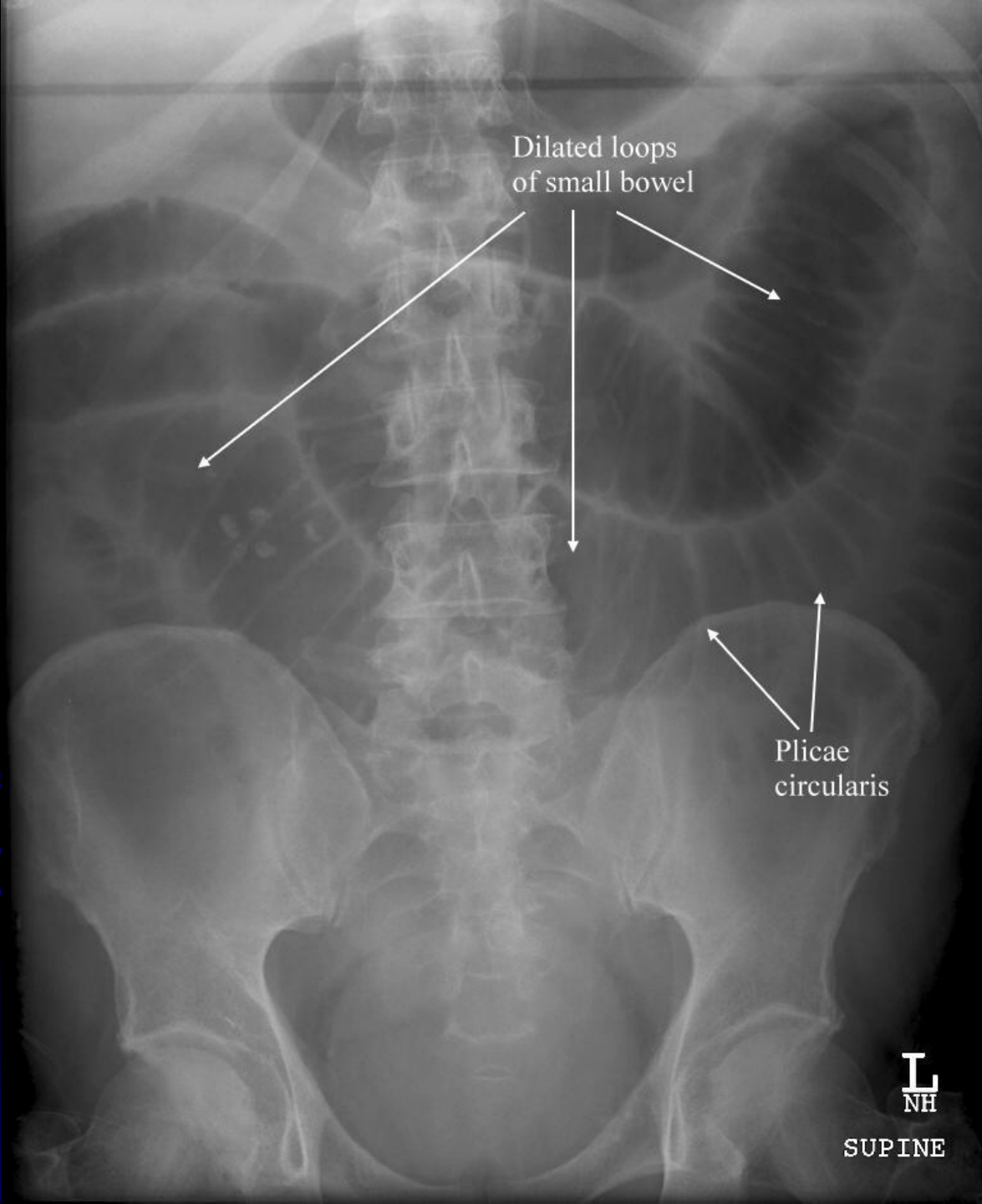
Normal
abdomen
radiograph

R
AK



SBO

R
23



Dilated loops
of small bowel

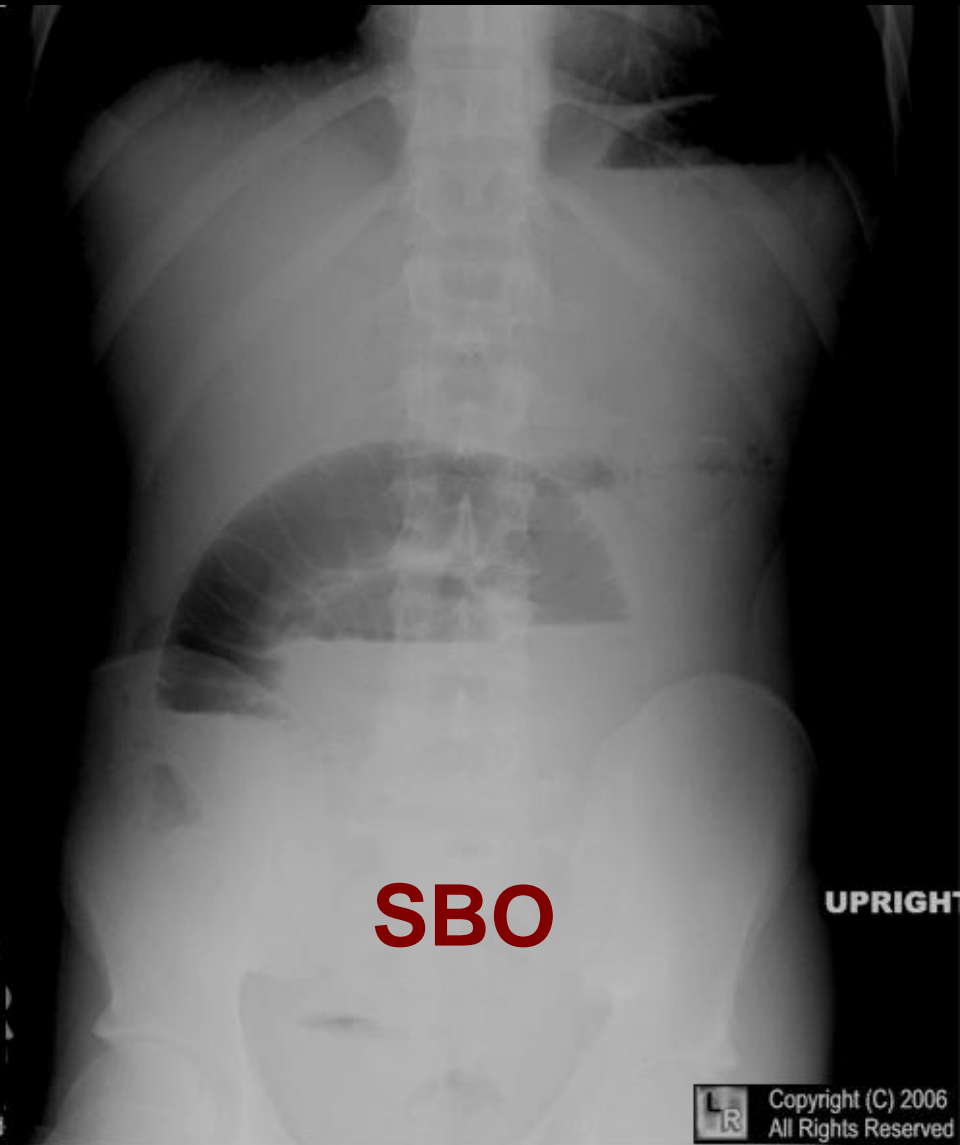
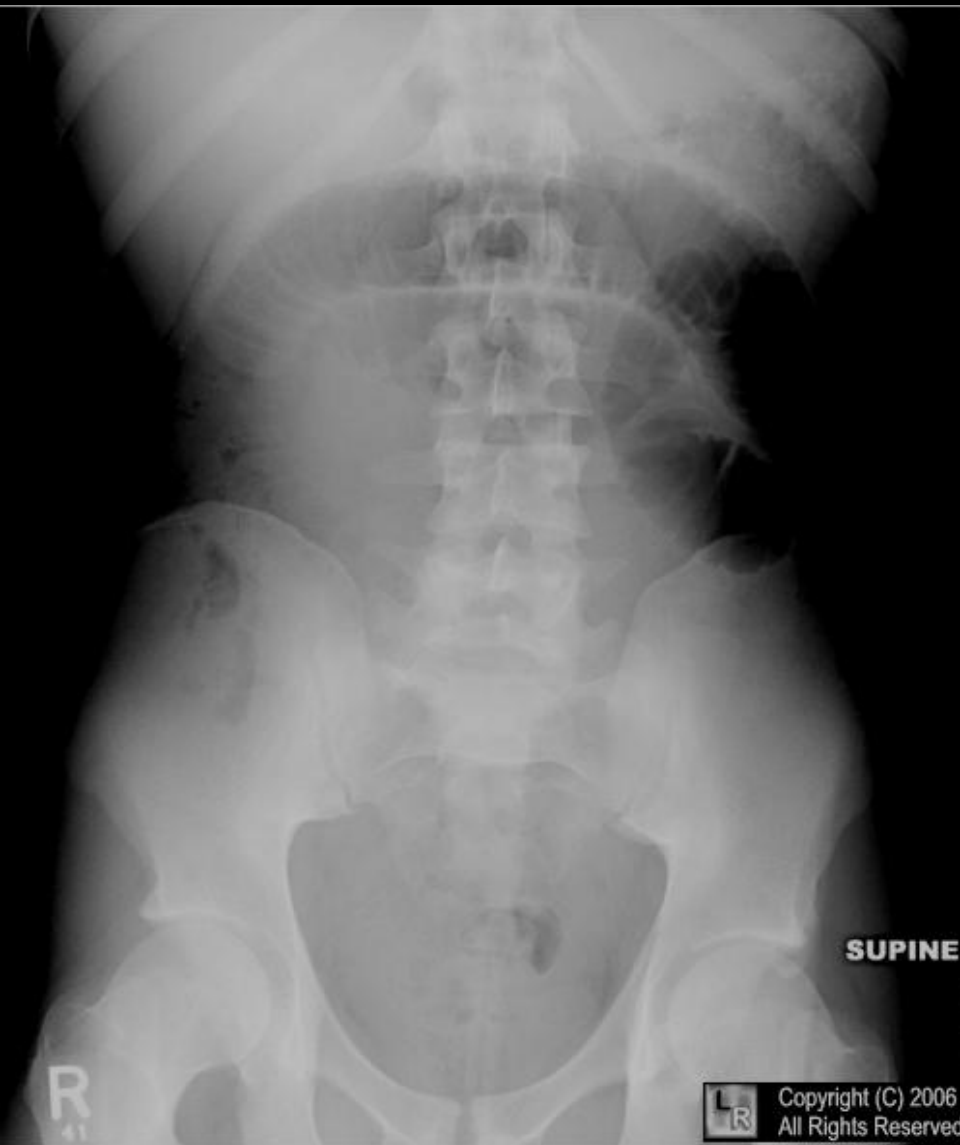
Plicae
circularis

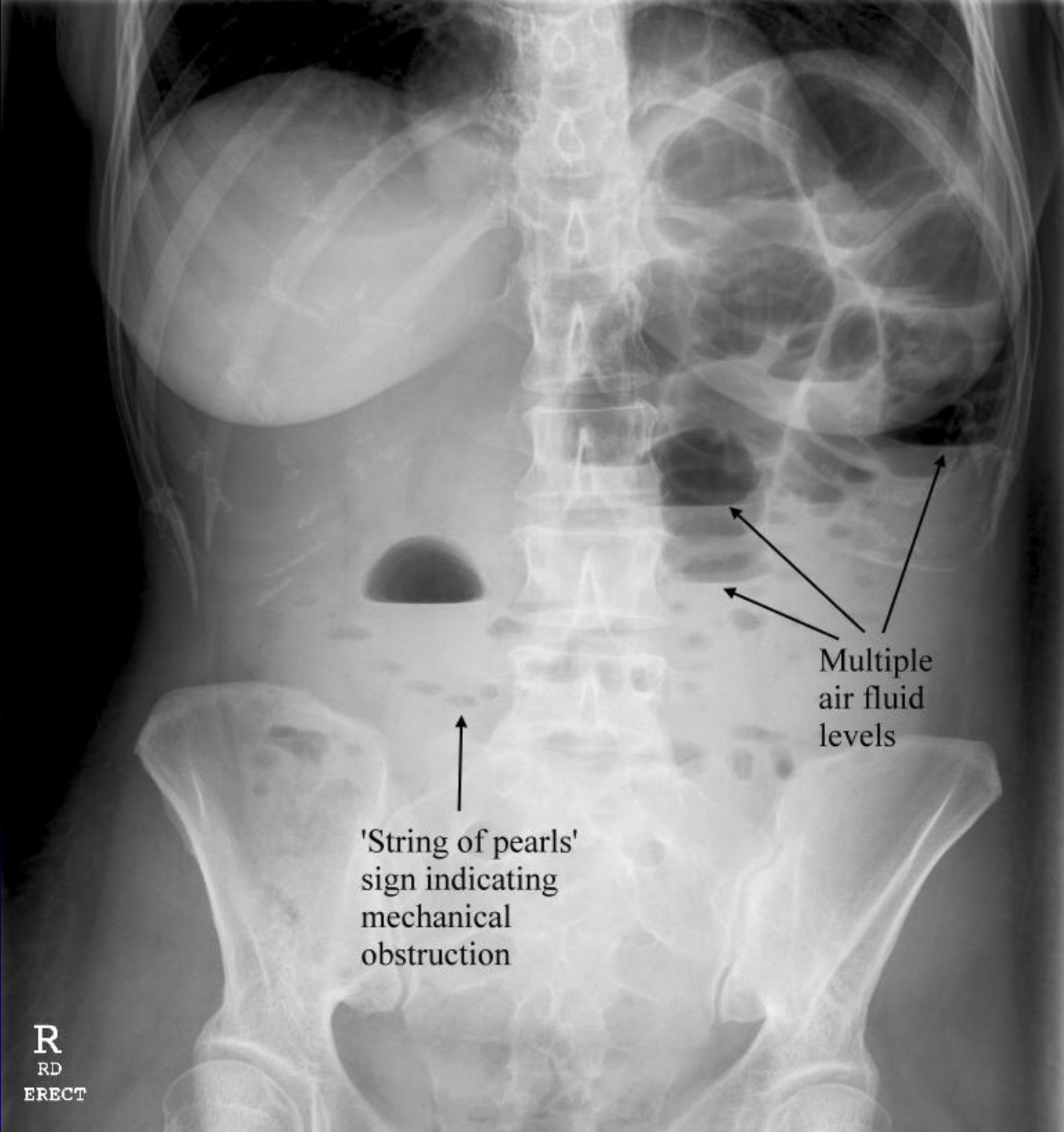
SBO

L
NH

SUPINE





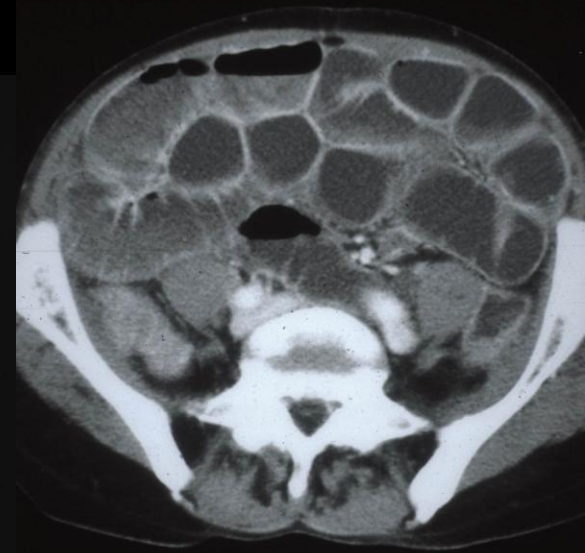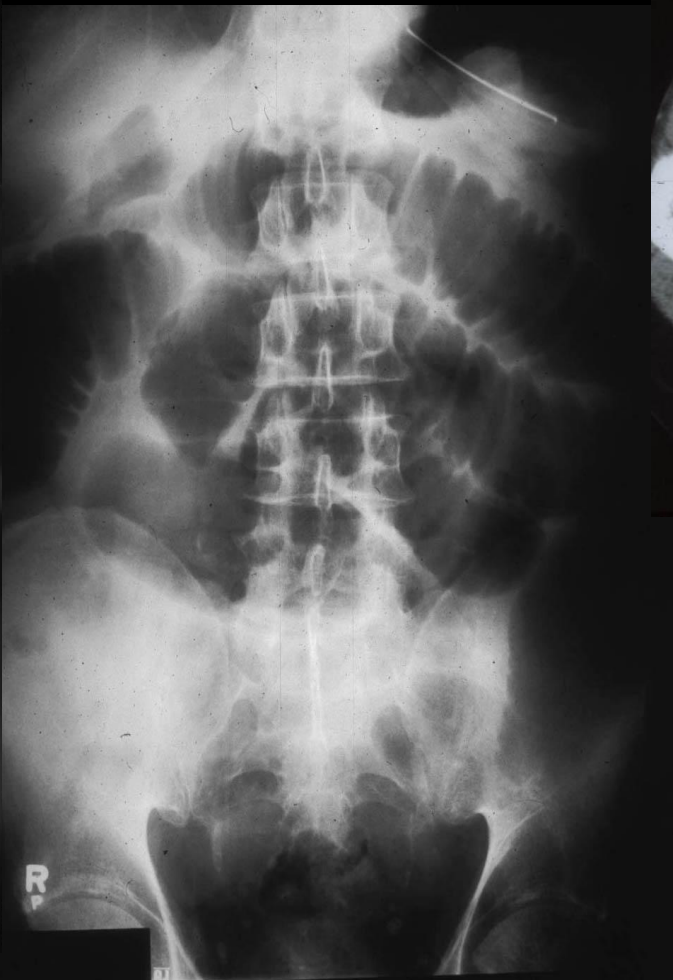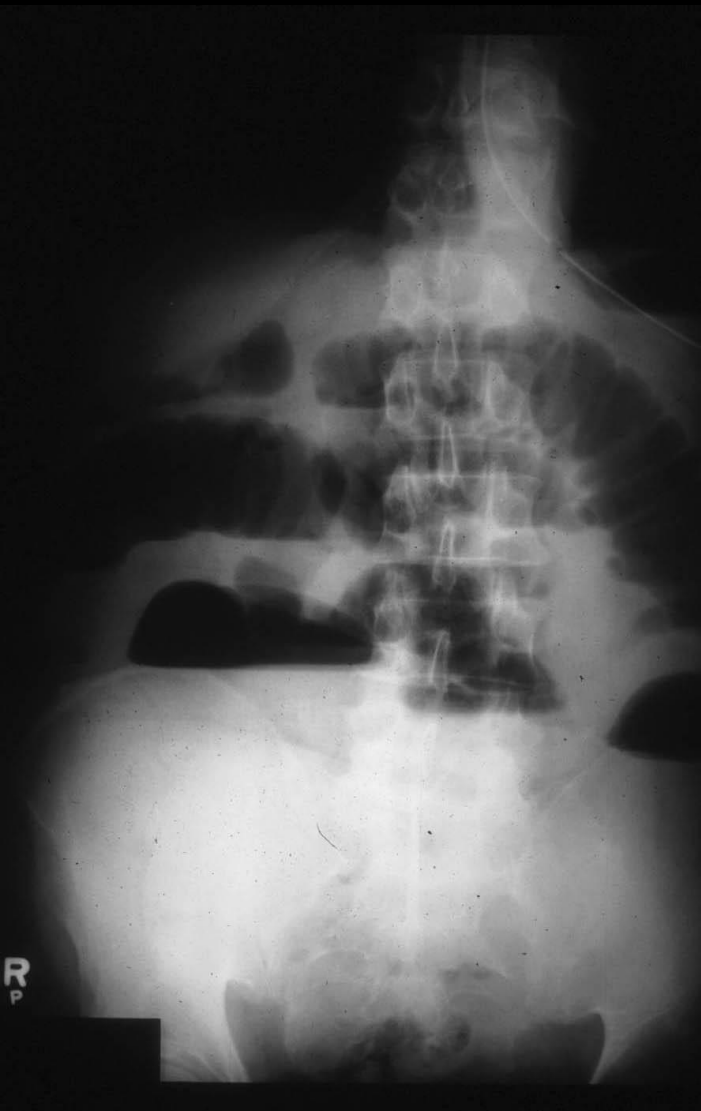


'String of pearls'
sign indicating
mechanical
obstruction

Multiple
air fluid
levels

SBO

R
RD
ERECT



SBO

StDt: 10/18/2009
StTm: 9:46:30 PM

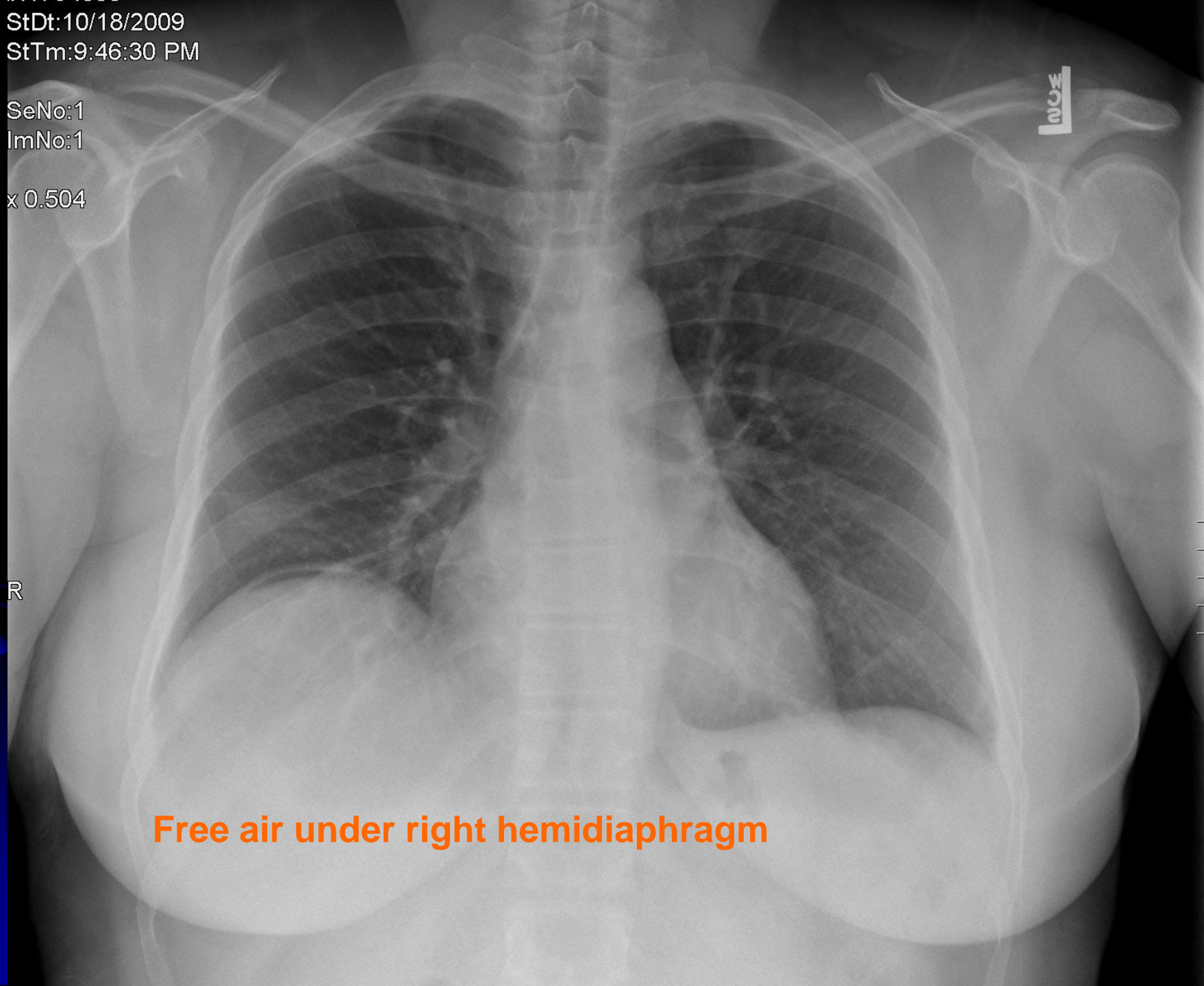
SeNo: 1
ImNo: 1

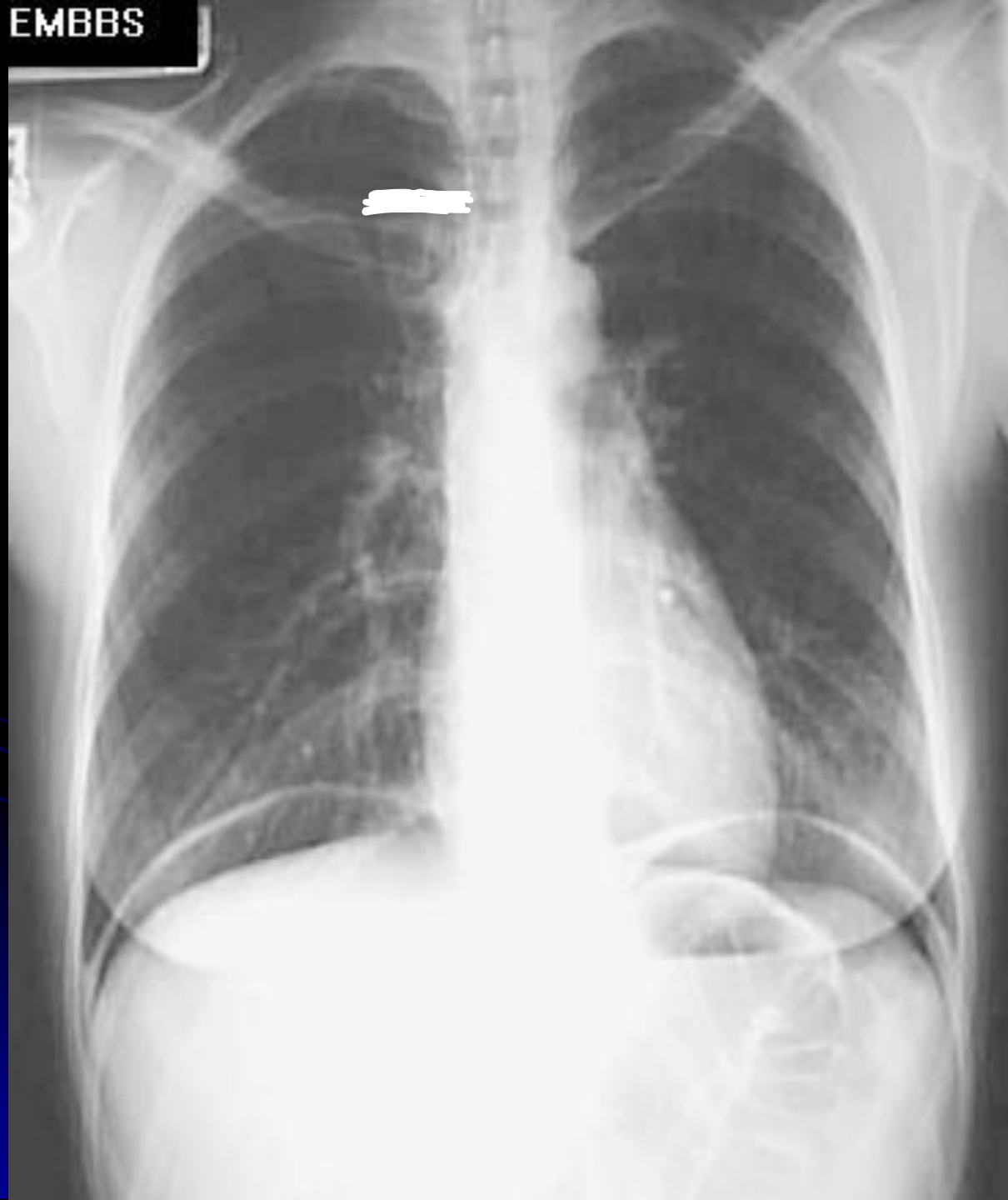x 0.504

MCW

R

Free air under right hemidiaphragm



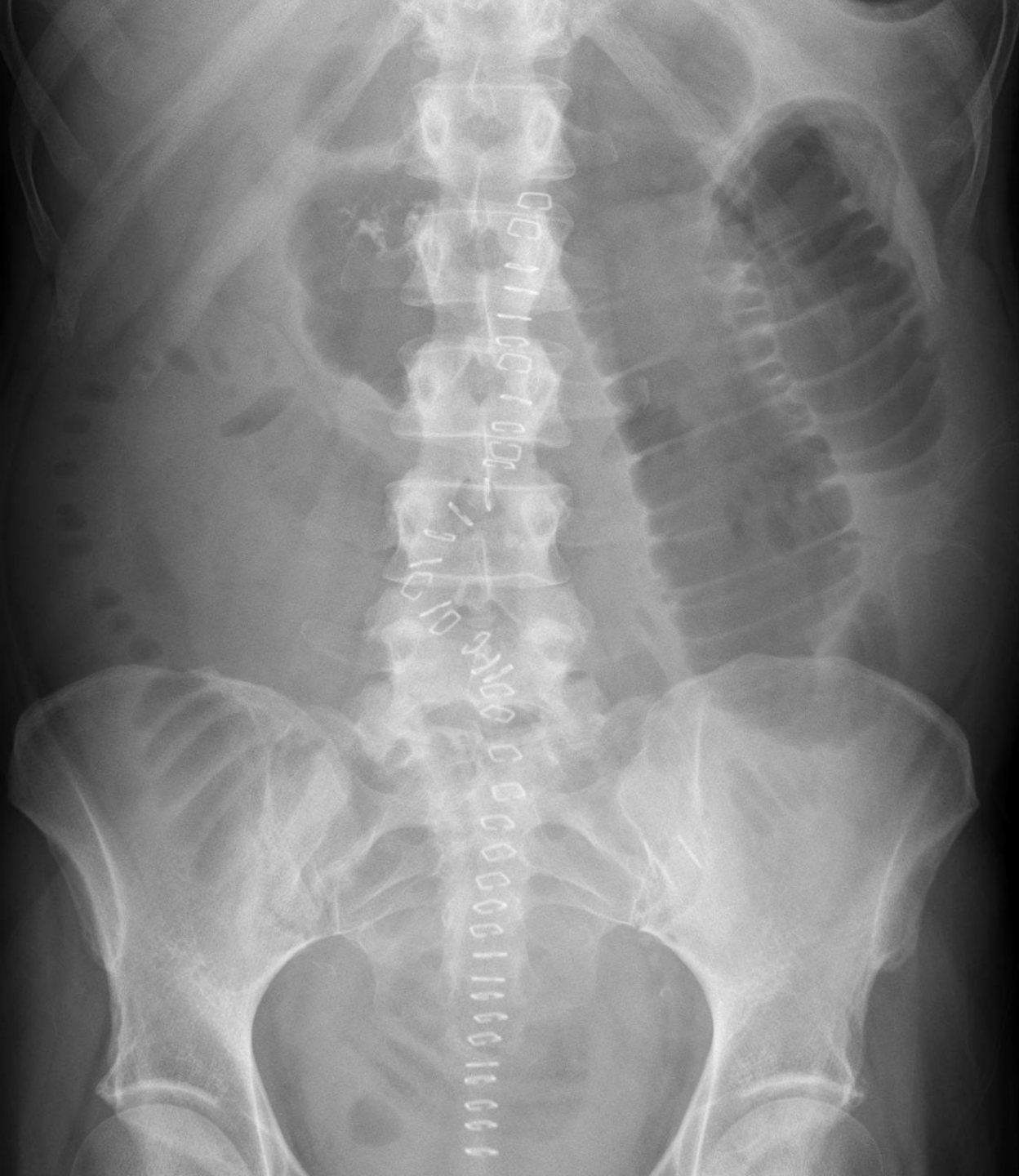


**PNEUMO
PERITONEUM**

1/18/2009
10:09:07 AM

3
1
3

R
supine



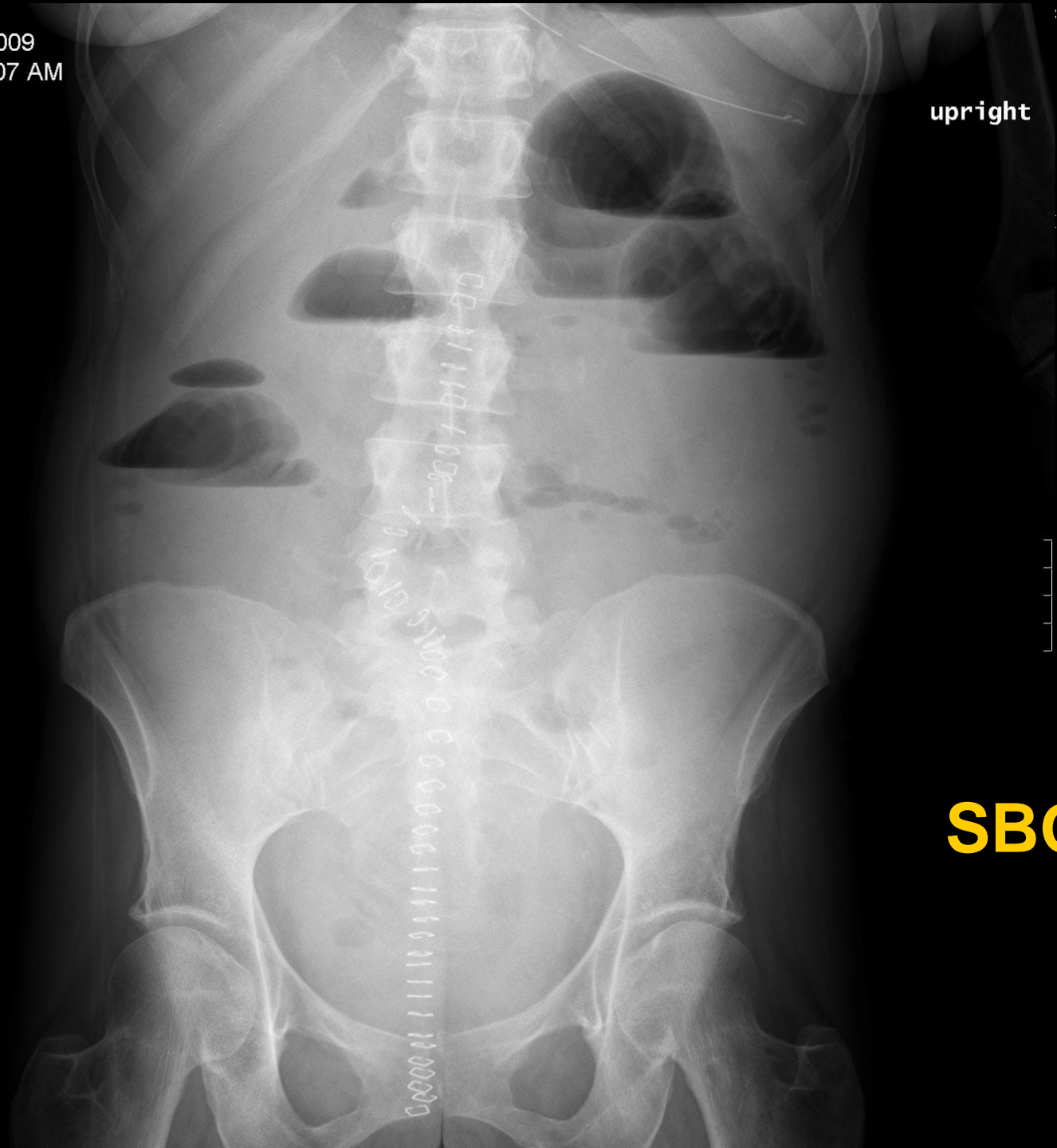2178
1/18/2009
10:09:07 AM

2
1
6

upright

R

SBO



1/2009
2:40 AM

|
|

Rigler's Sign: free air

┌
├
├
├
└

R

**SUPINE
Portable**



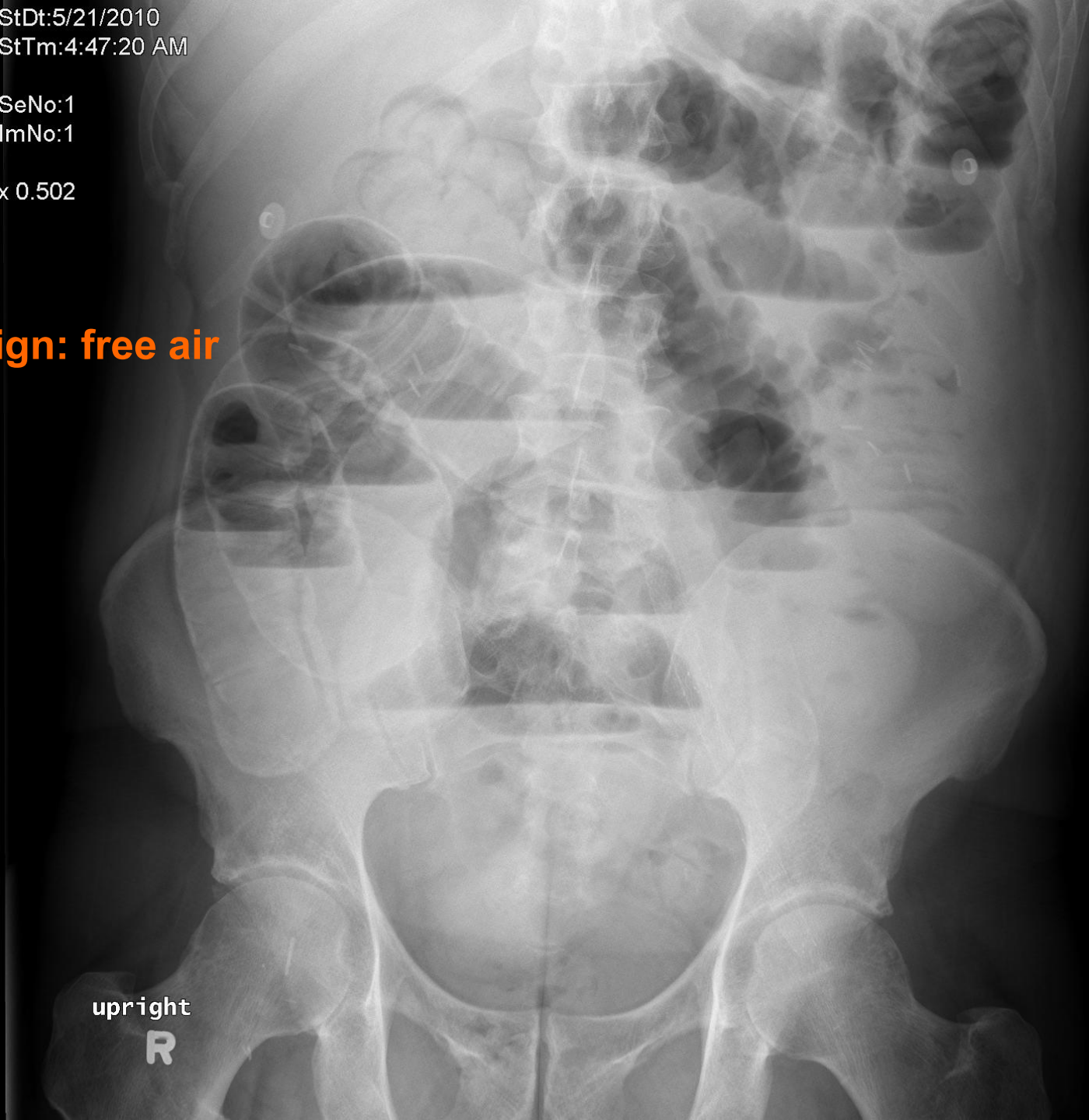StDt:5/21/2010
StTm:4:47:20 AM

SeNo:1
ImNo:1

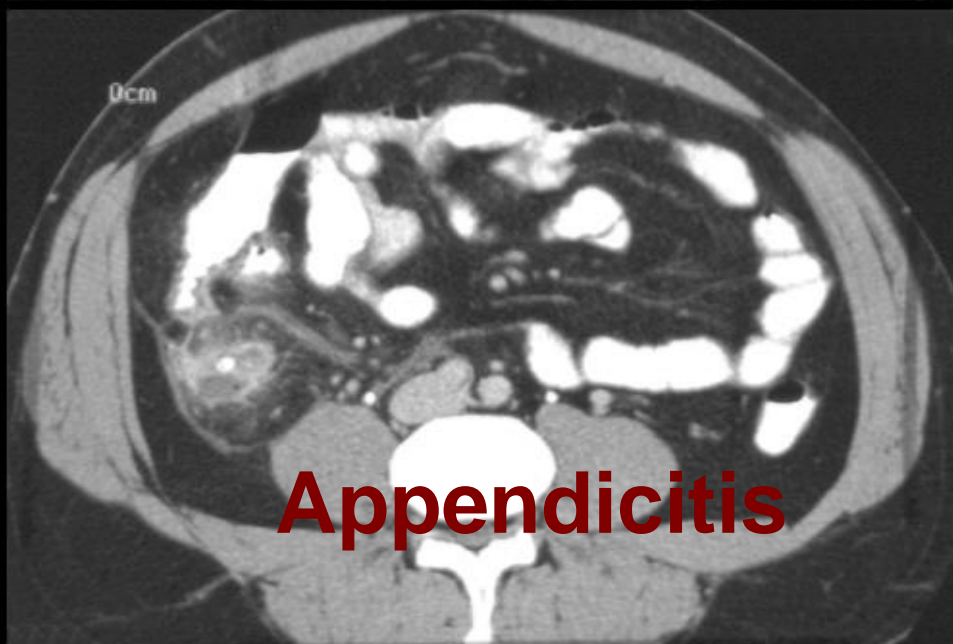
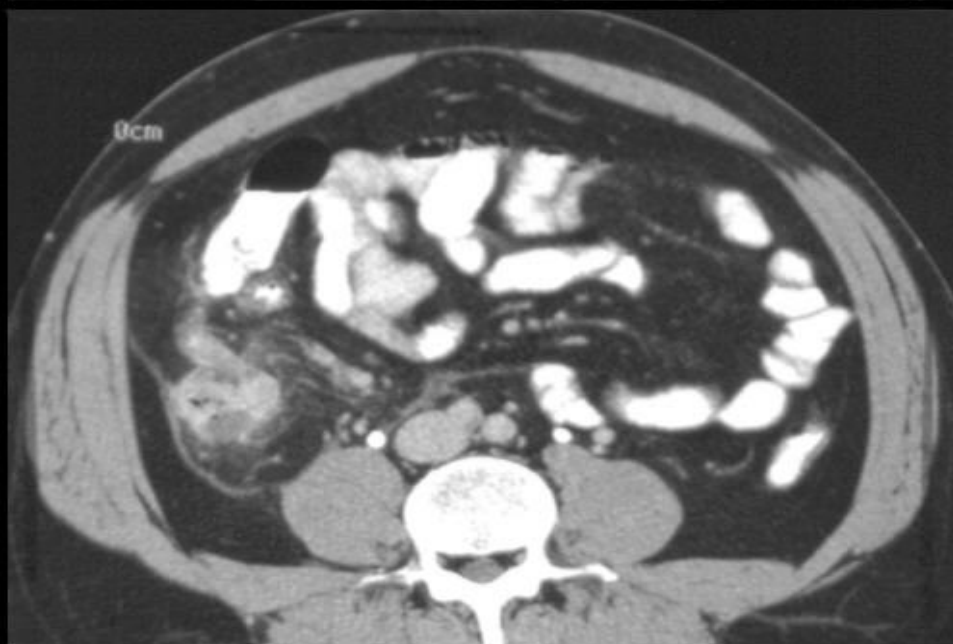
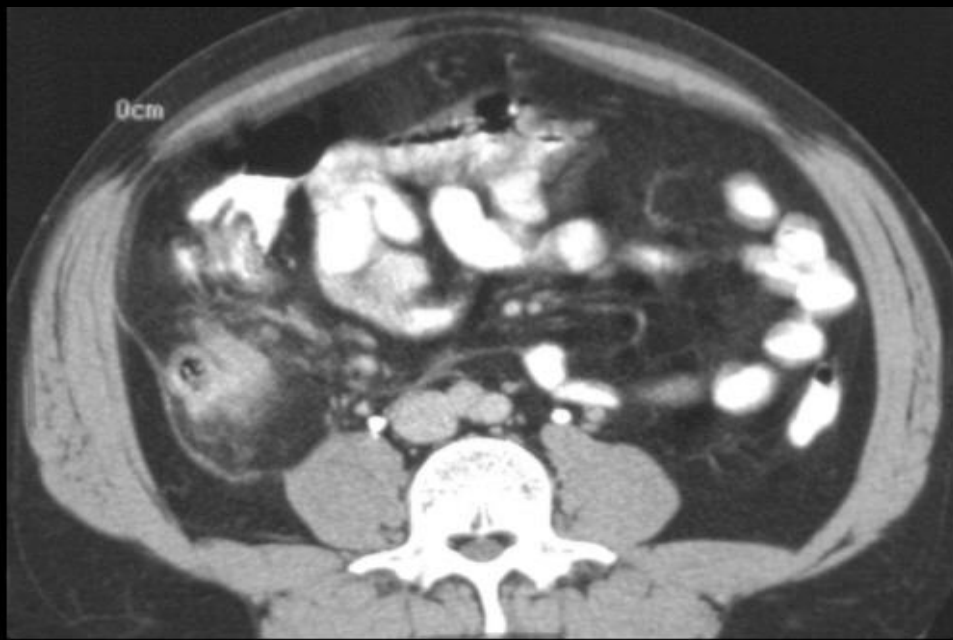
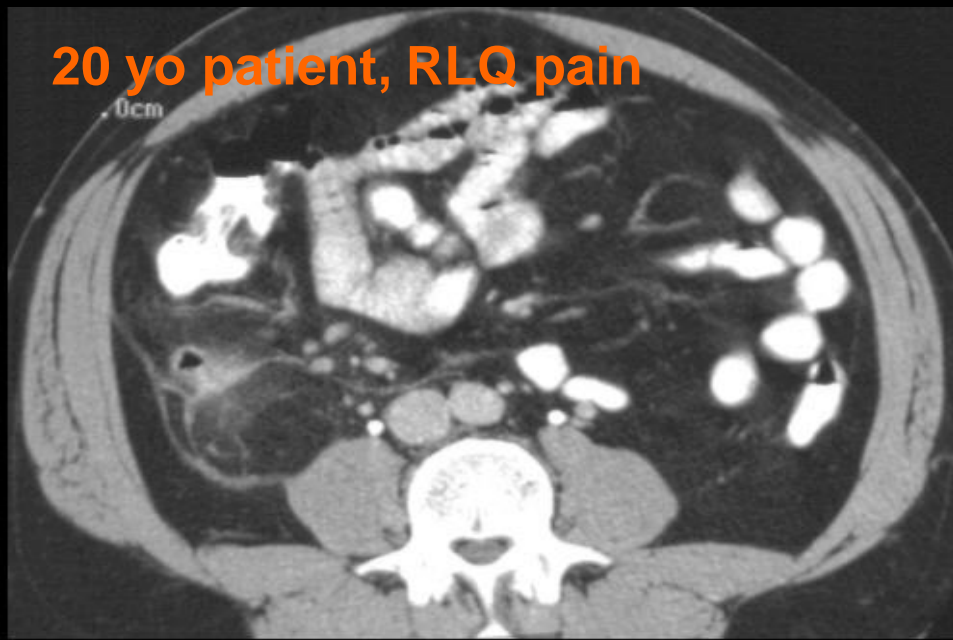
x 0.502

Rigler's Sign: free air

upright
R

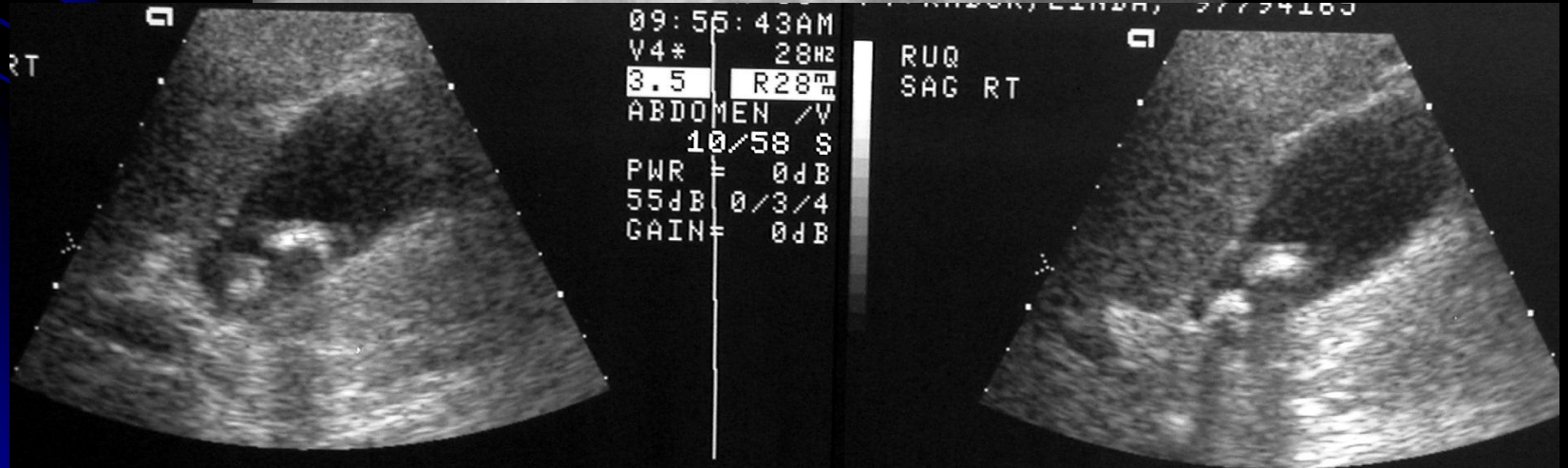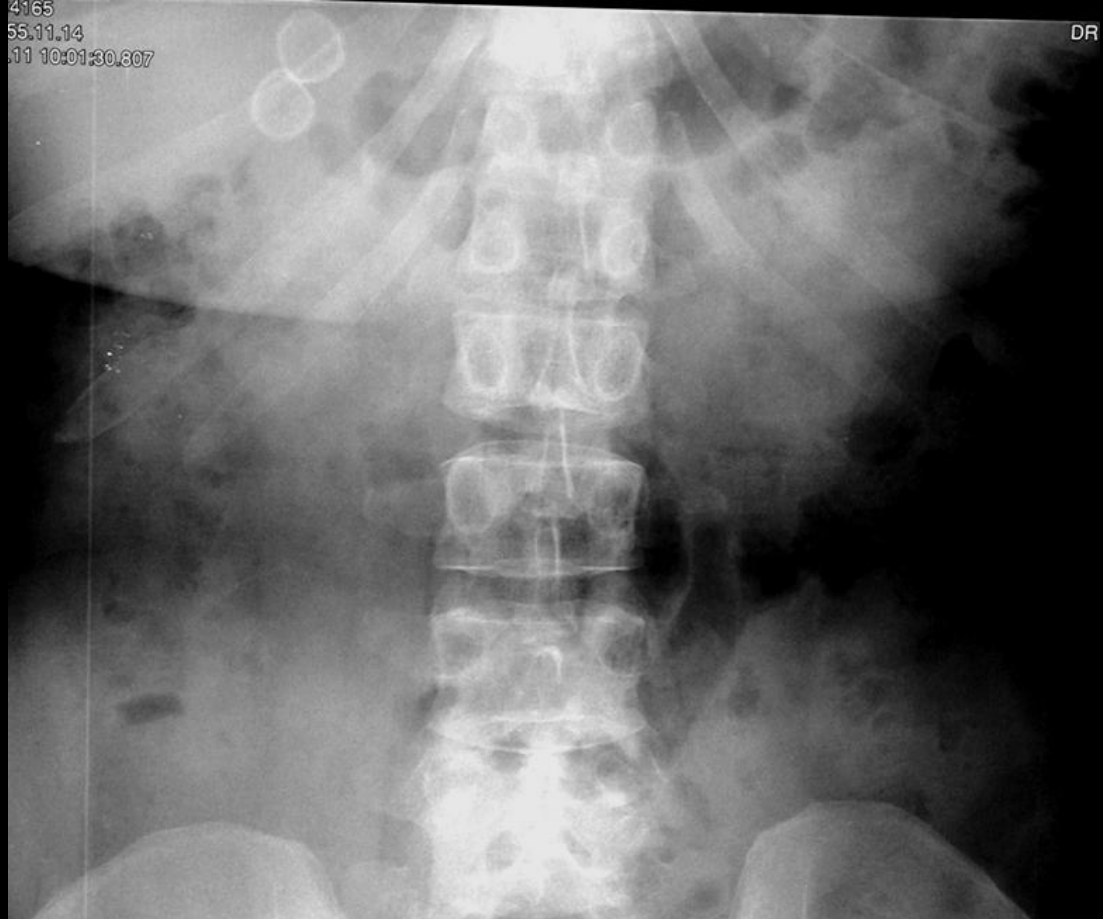


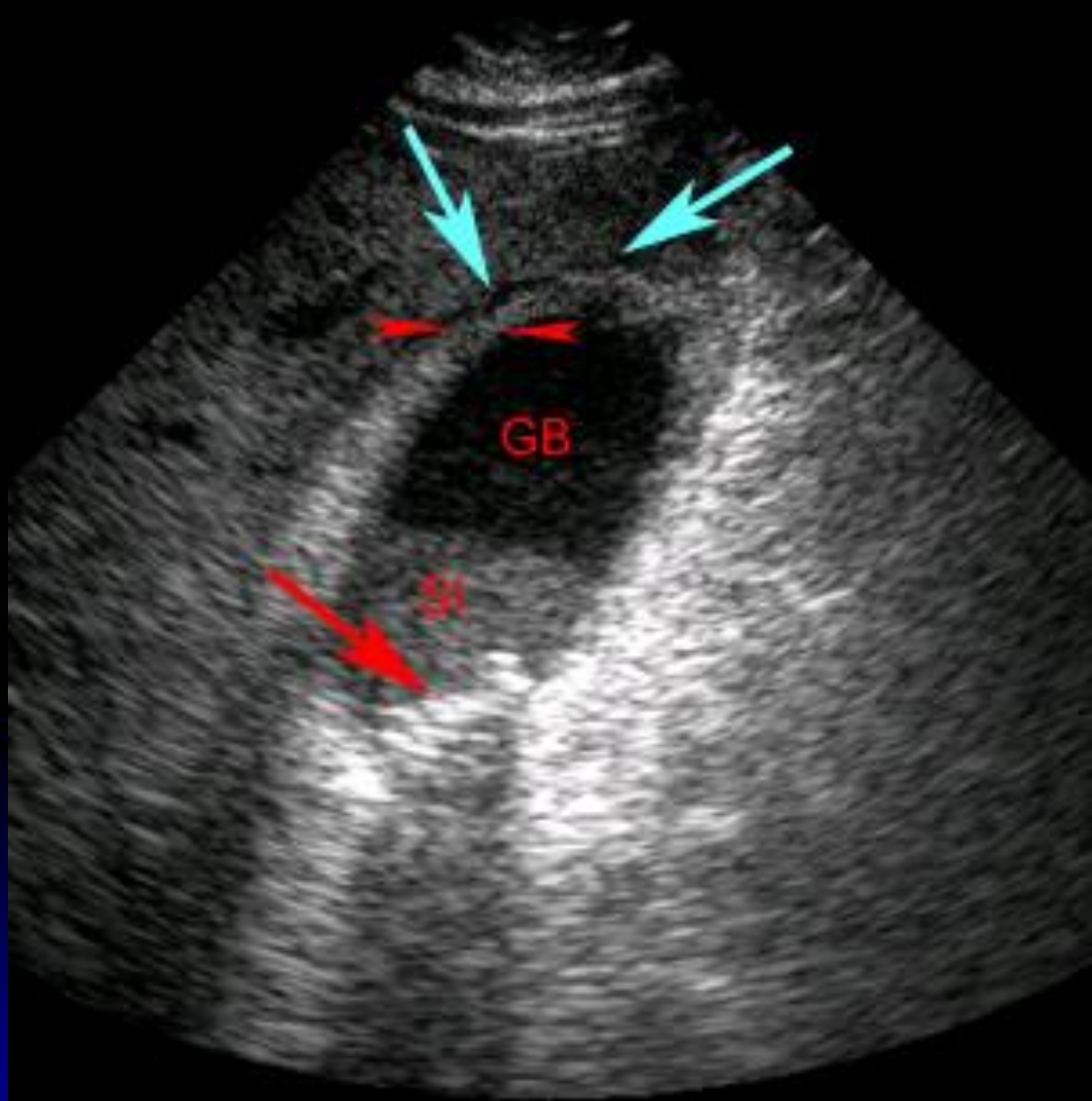
20 yo patient, RLQ pain



Hx: RUQ
PAIN

gallstones





**Positive
Sonographic
Murphy's Sign**

**Acute
Cholecystitis**

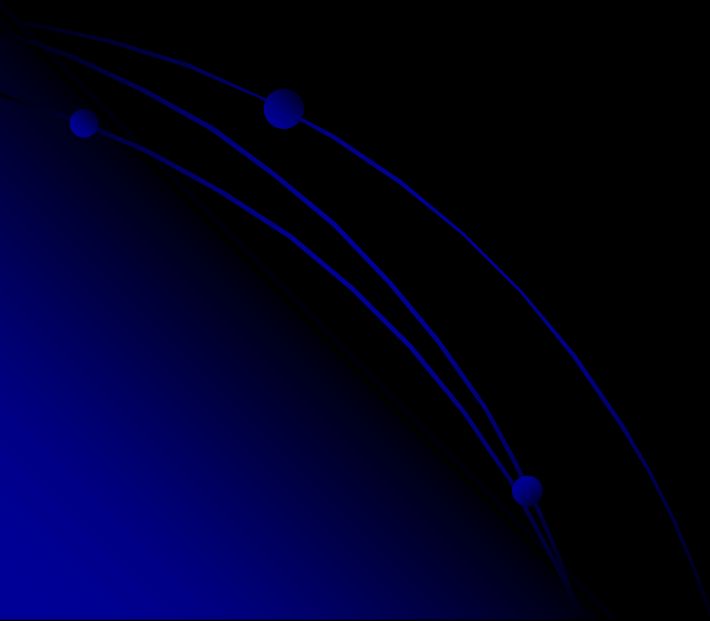
ABDOMEN REVIEW

-SBO


-Pneumoperitoneum

-Appendicitis

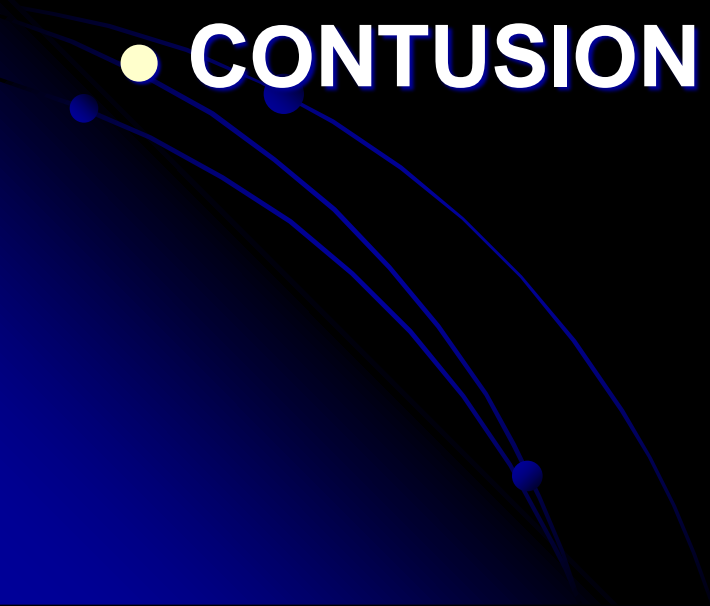
-Cholecystitis

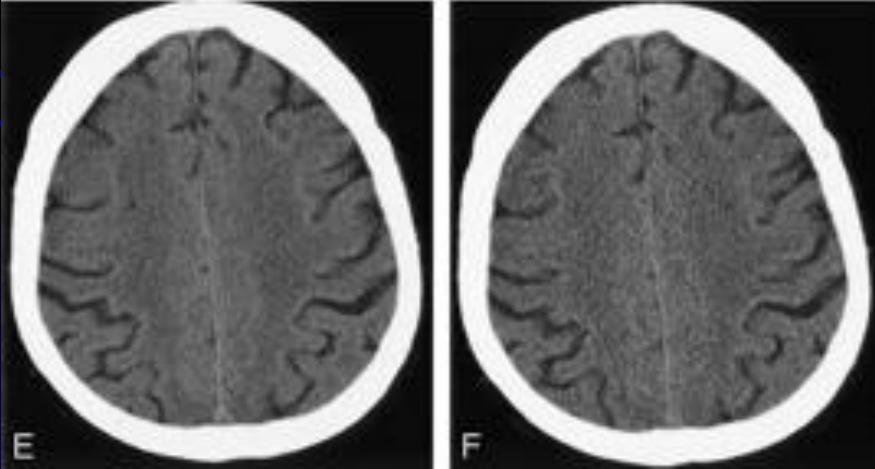
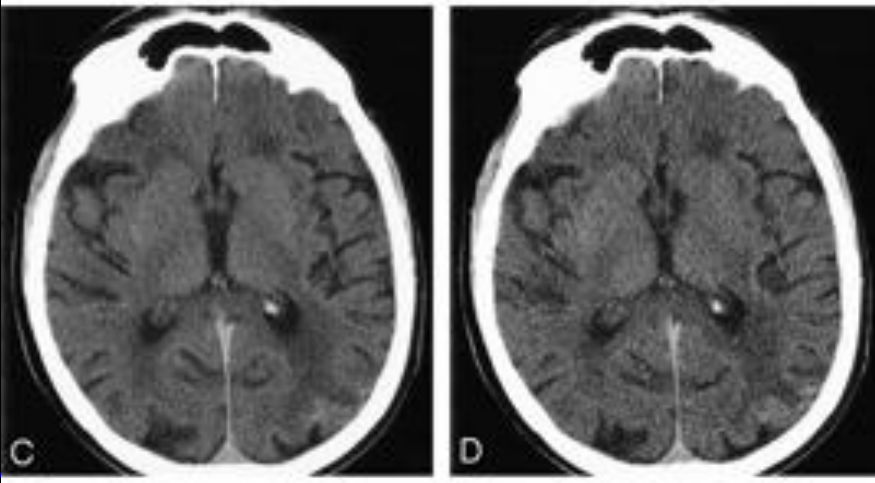
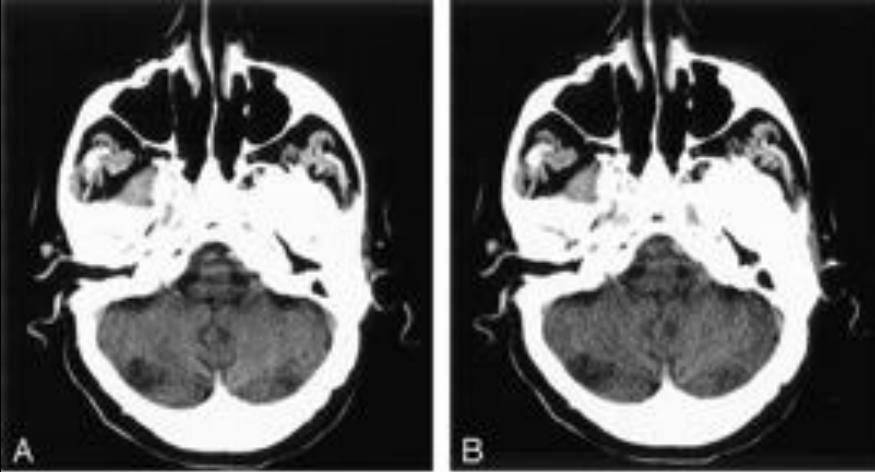


NEURO

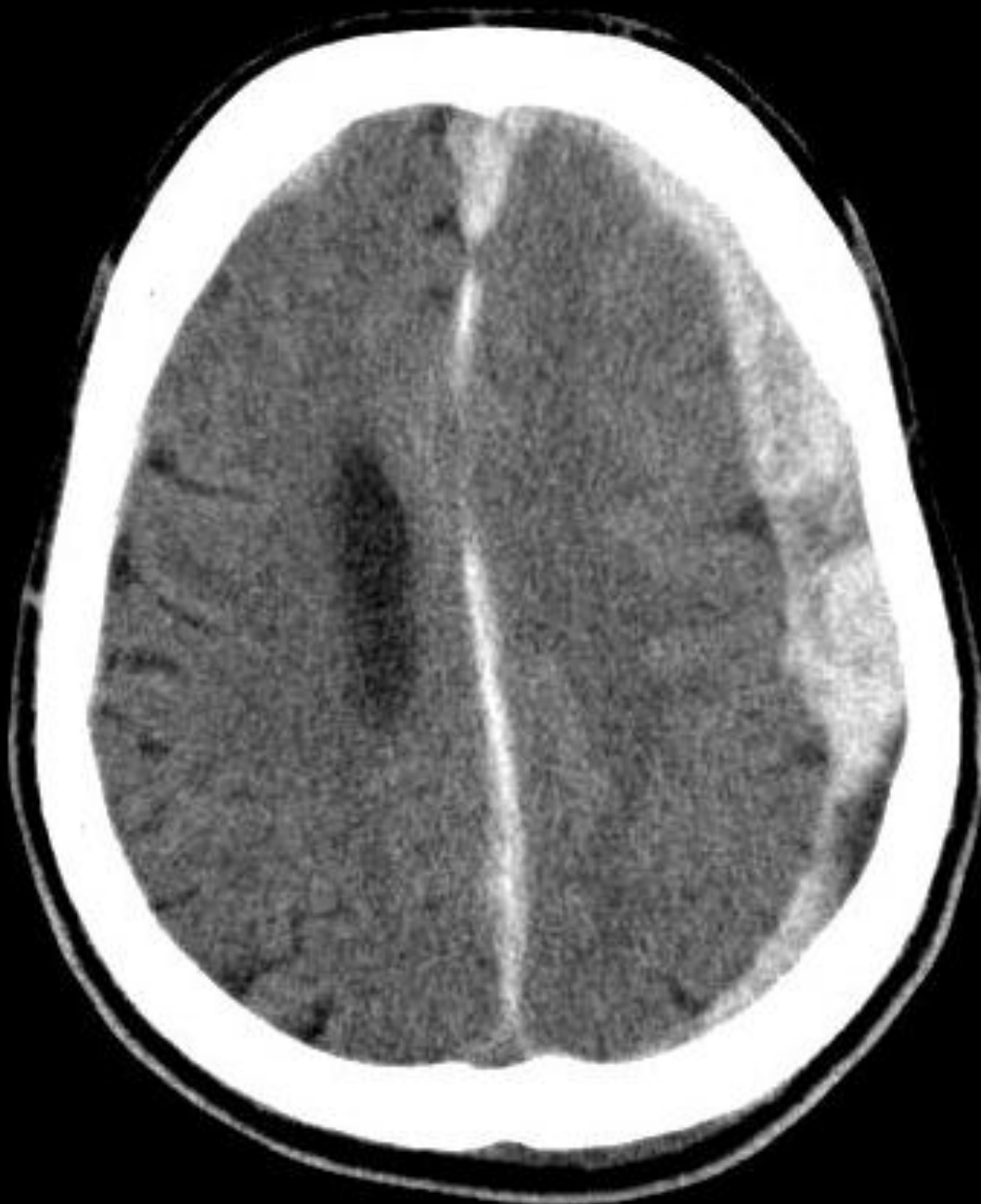

TRAUMA - NEURORADIOLOGY

- **SUBDURAL HEMATOMA**
 - **SUBARACHNOID HEMORRHAGE**
 - **EPIDURAL HEMATOMA**
 - **CONTUSION**
- 



Normal head CT

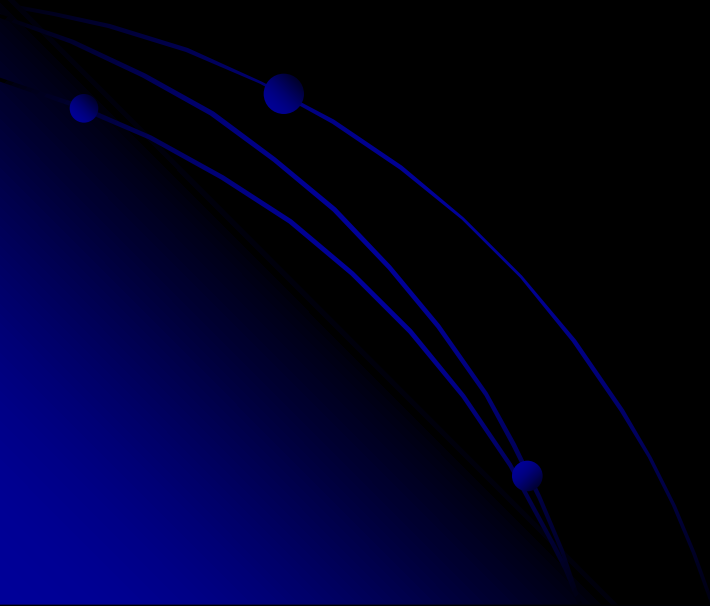
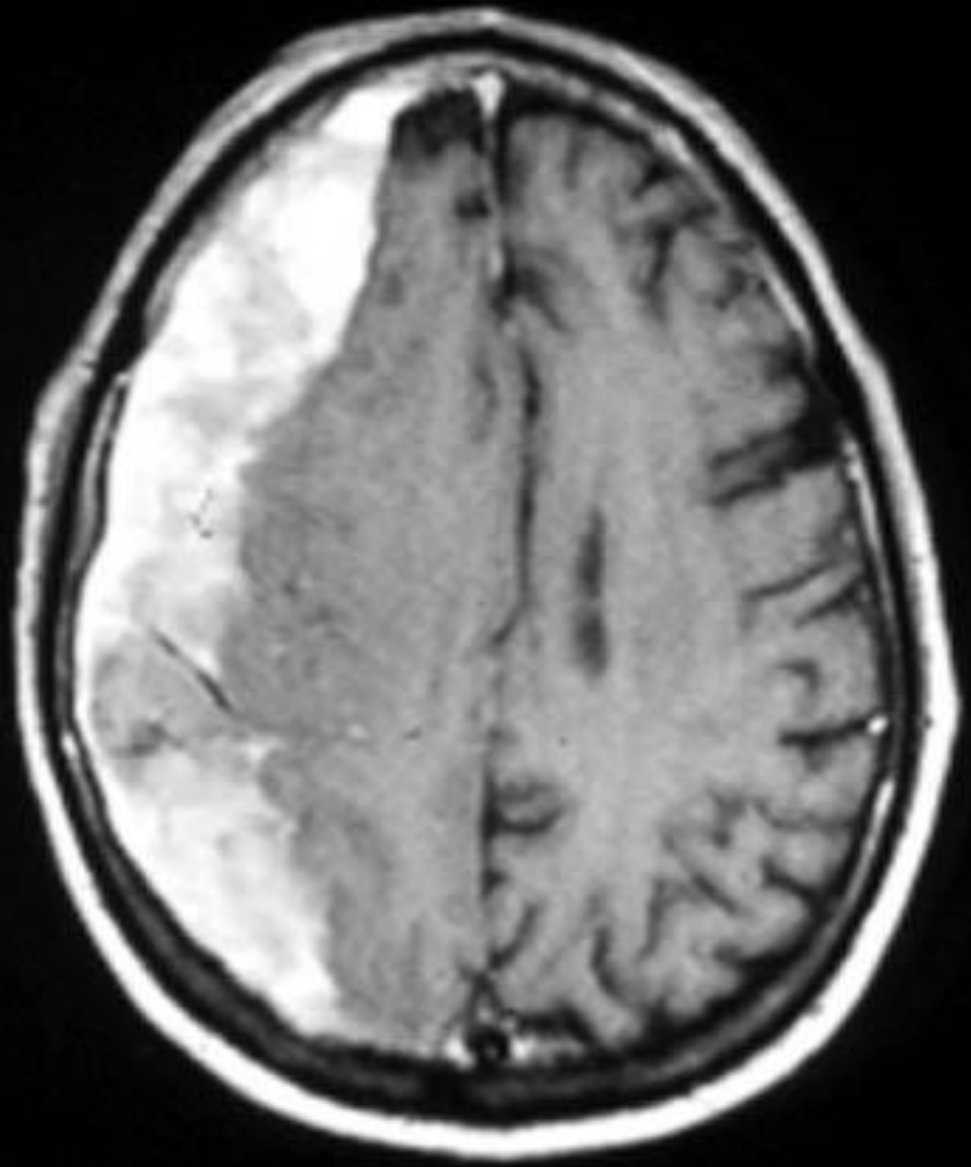


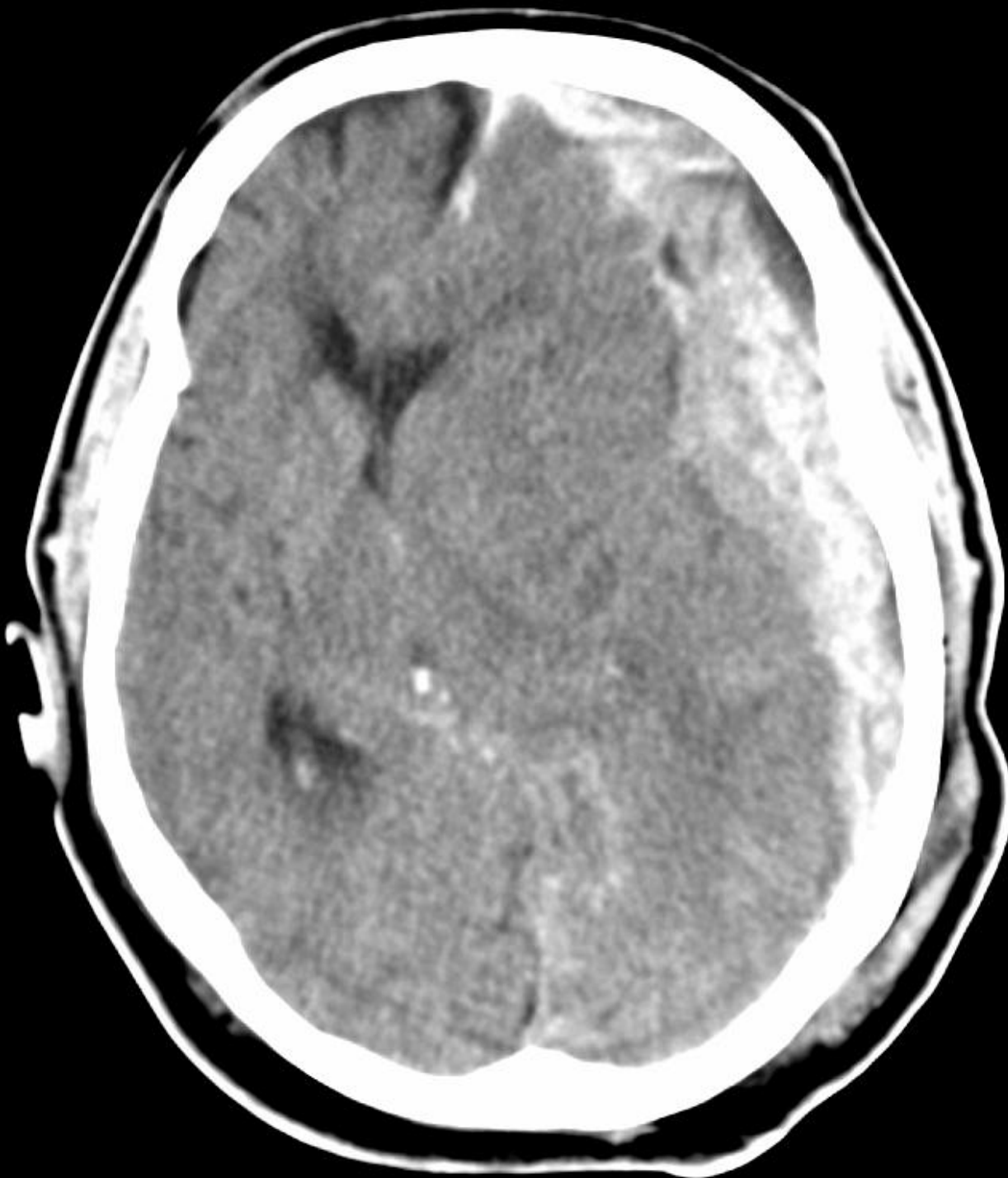Hx: trauma

**Subdural
Hematoma**

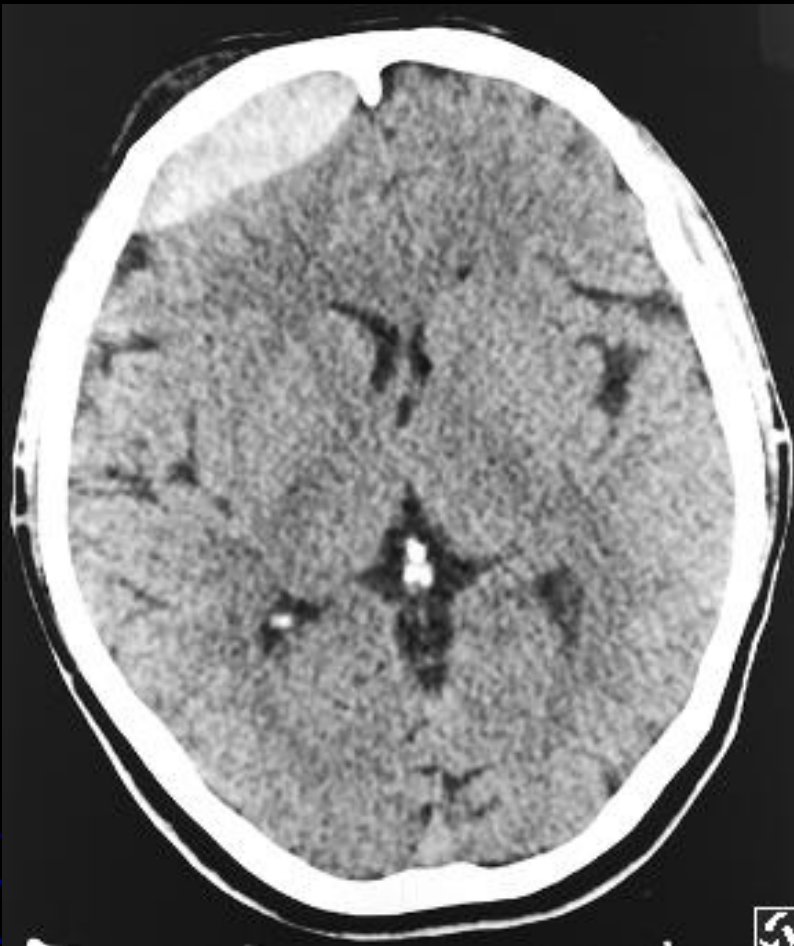Hx: trauma

**Subdural
Hematoma**

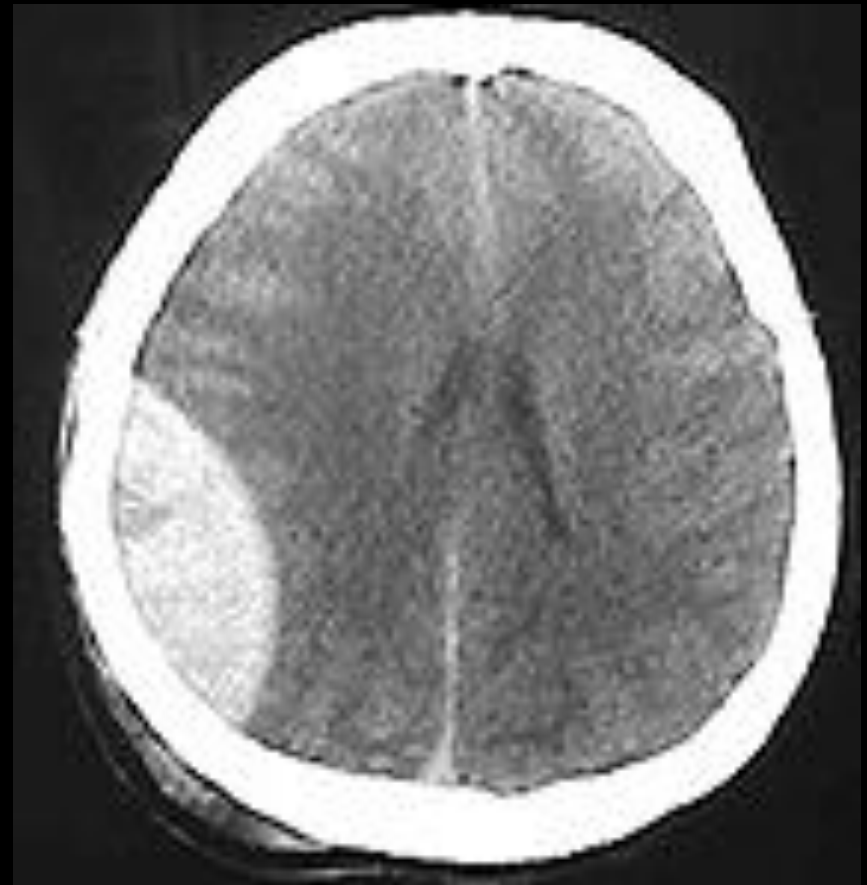



**Subdural
Hematoma**

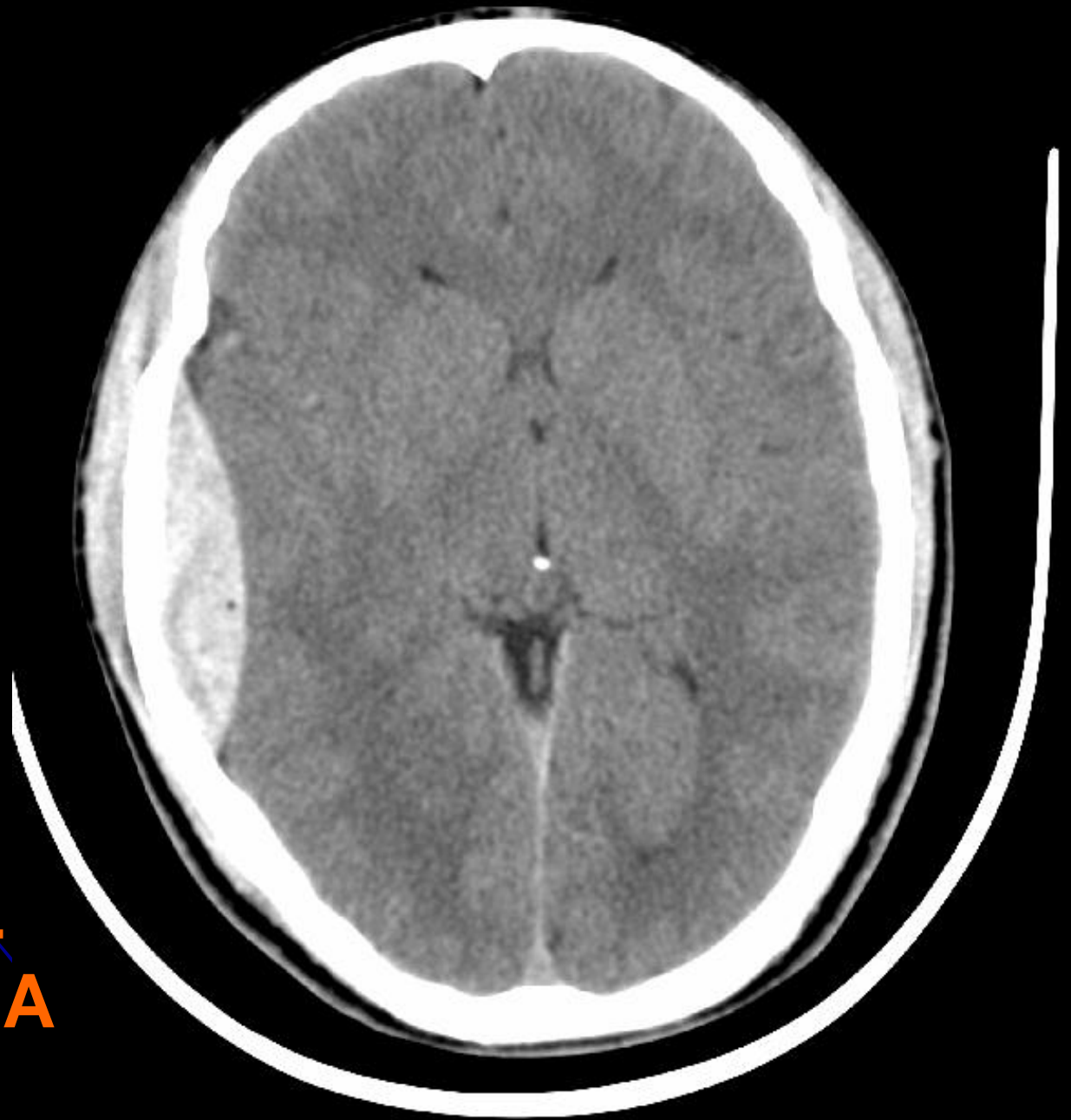


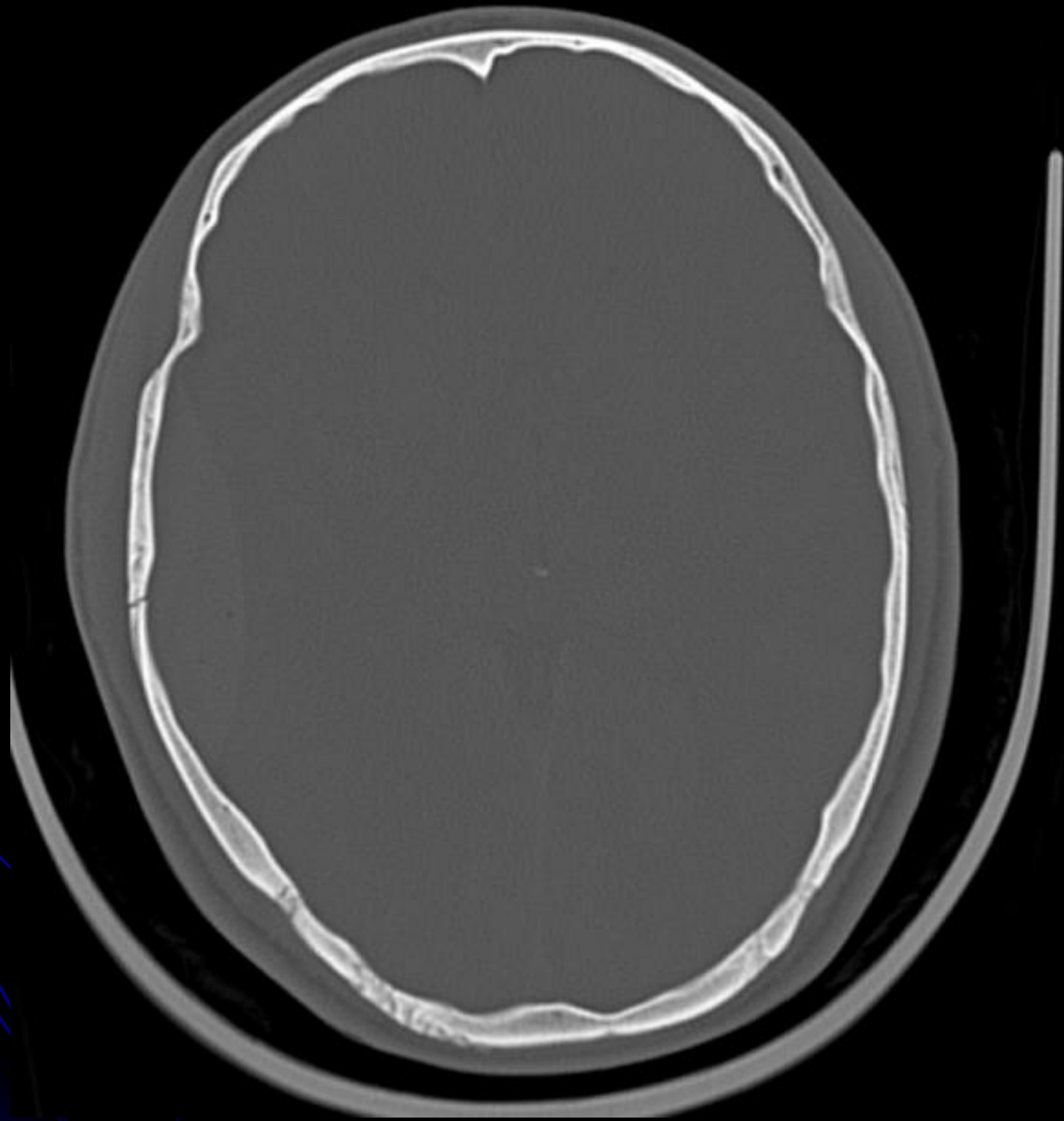
Does not cross suture lines



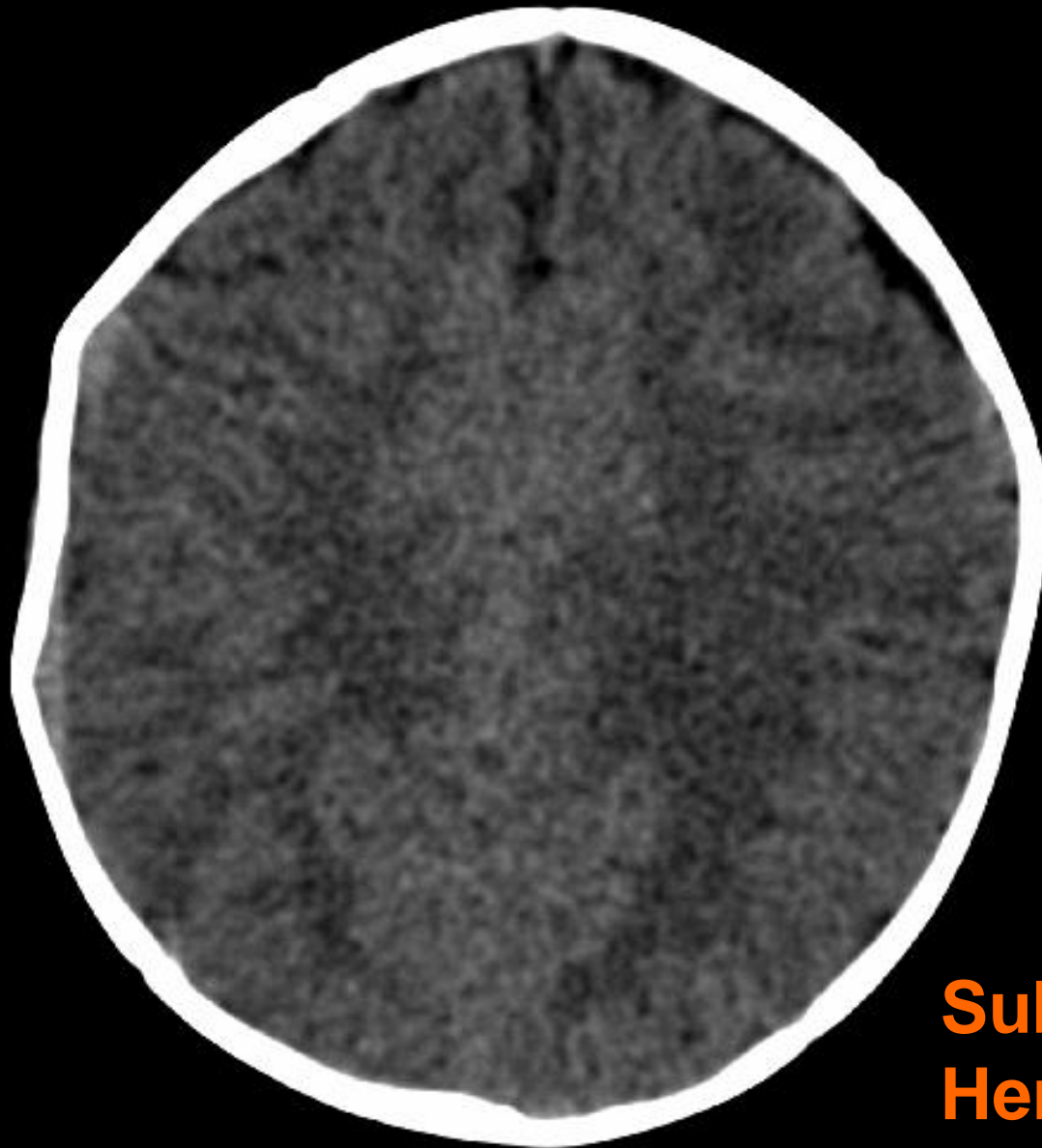**EPIDURAL
HEMATOMA**

**EPIDURAL
HEMATOMA**



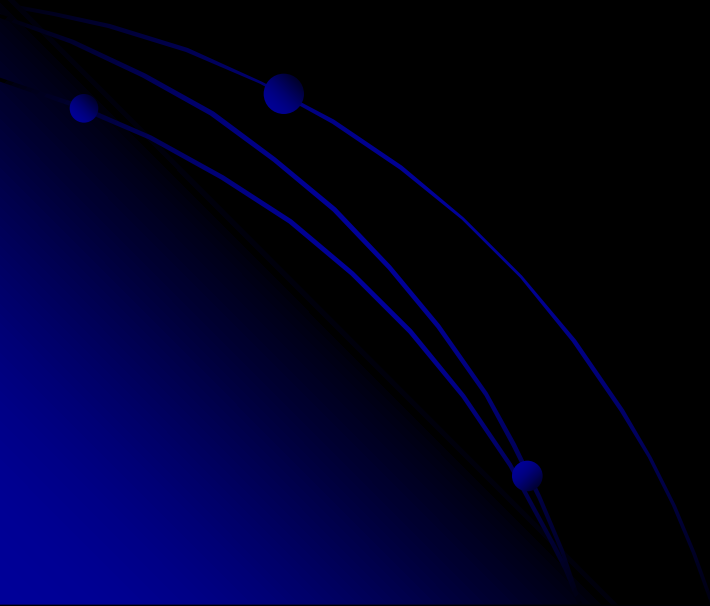


+fracture

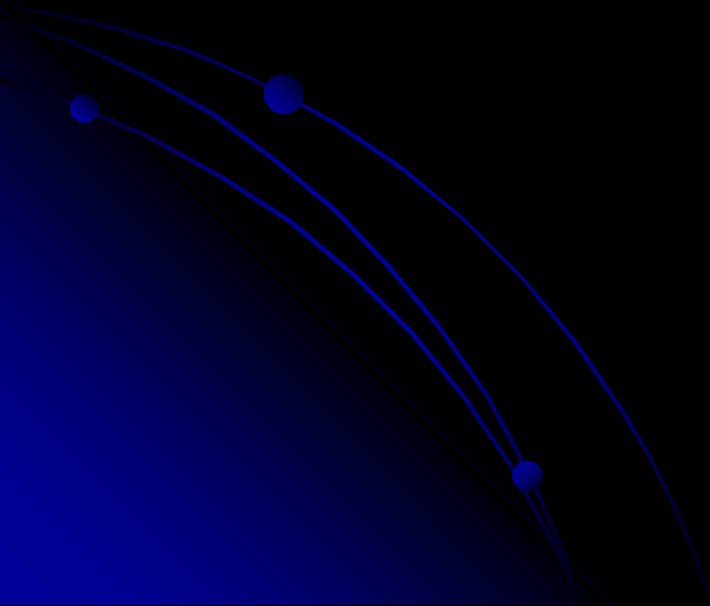


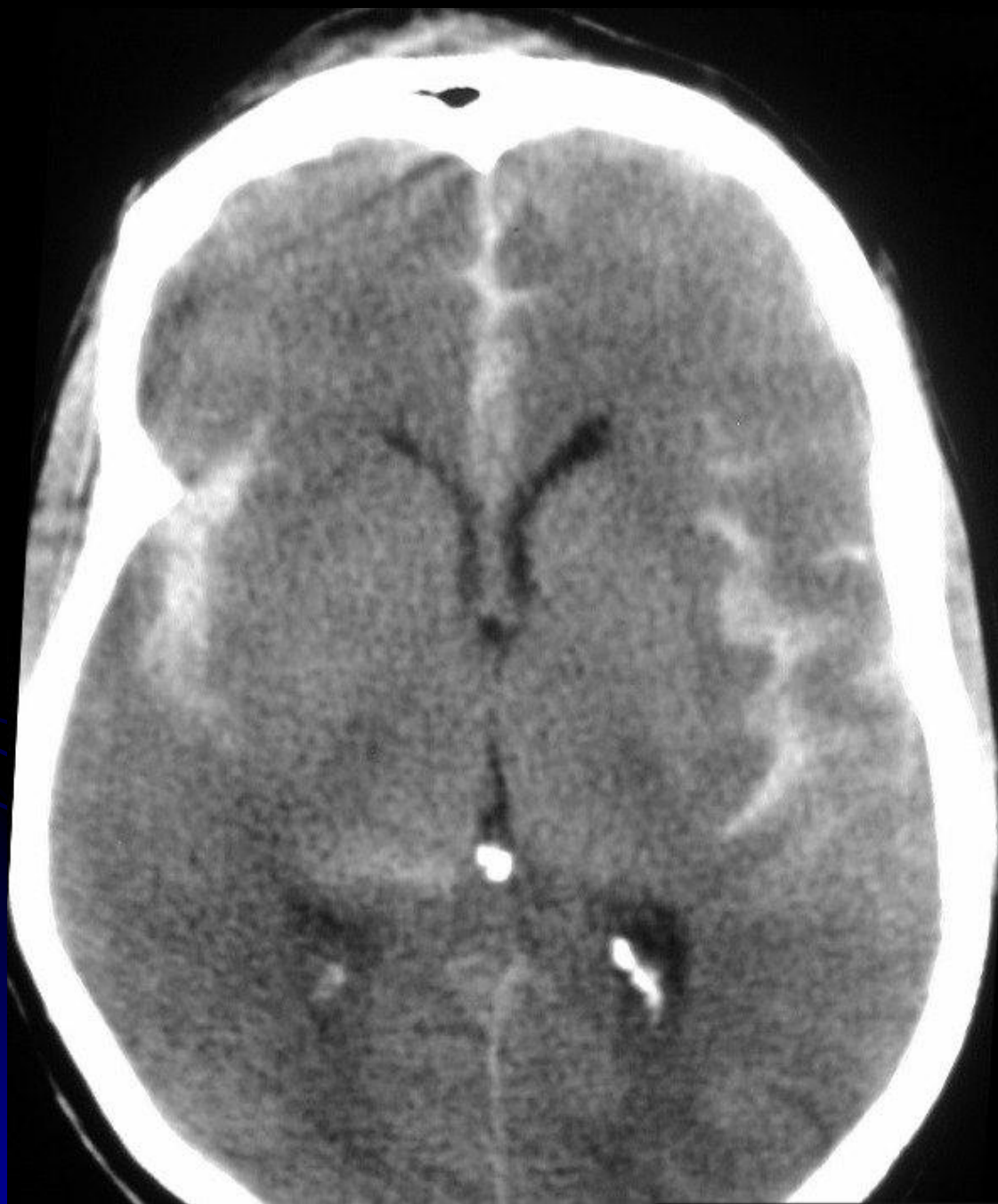**Subdural
Hematoma**

NEURORADIOLOGY

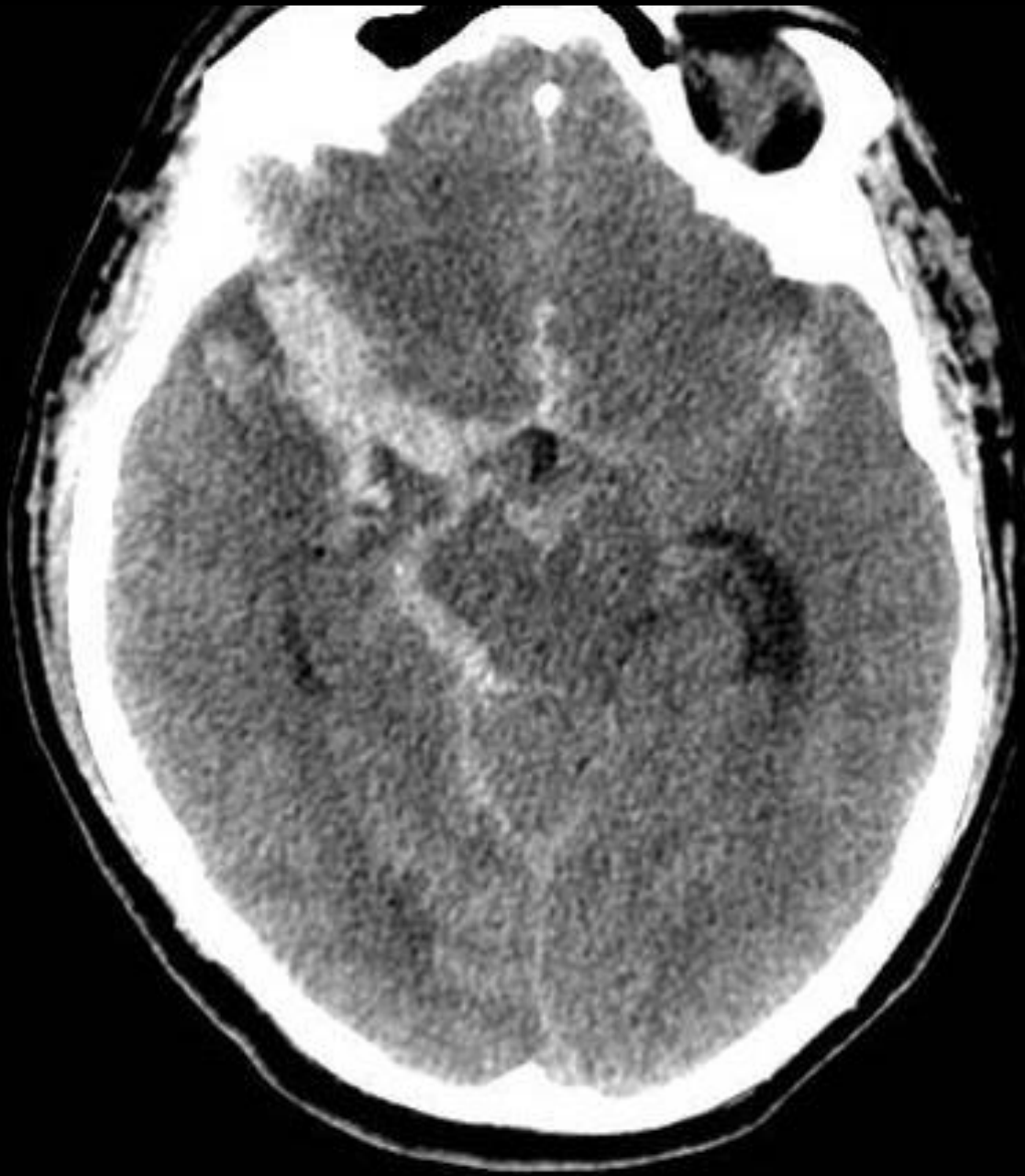
- SUBDURAL HEMATOMA
 - EPIDURAL HEMATOMA
 - **SUBARACHNOID HEMORRHAGE**
 - CONTUSION
- 

Subarachnoid Hemorrhage

- **CAUSES**
 - **TRAUMA**
 - **ANEURYSM**
- 

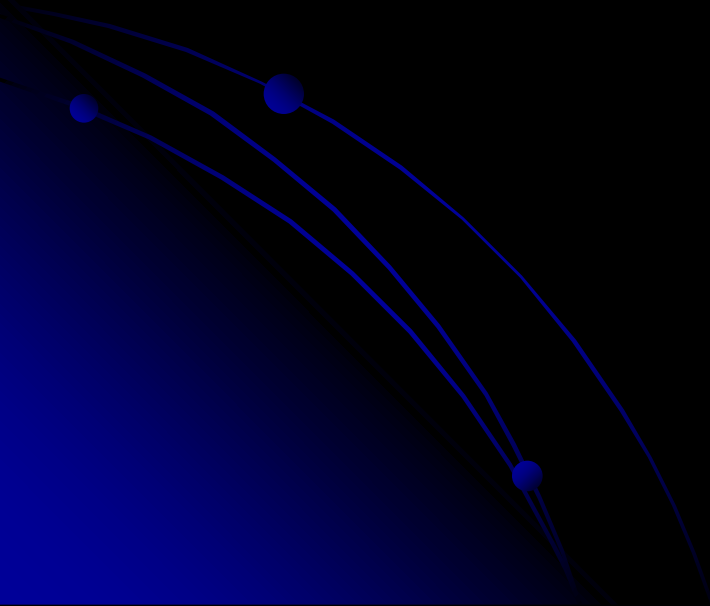


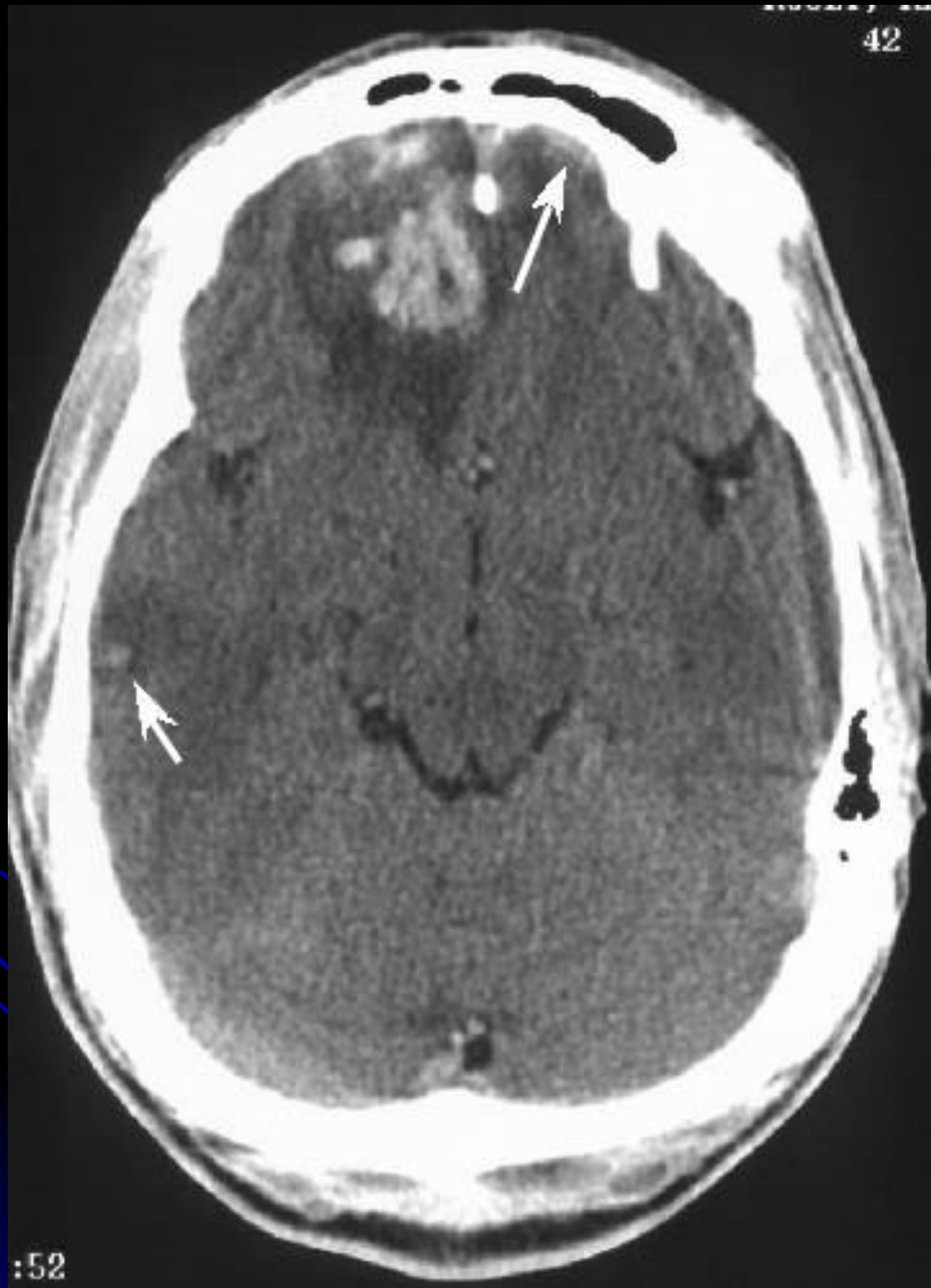**Traumatic
SAH**



**SAH secondary to
MCA aneurysm**

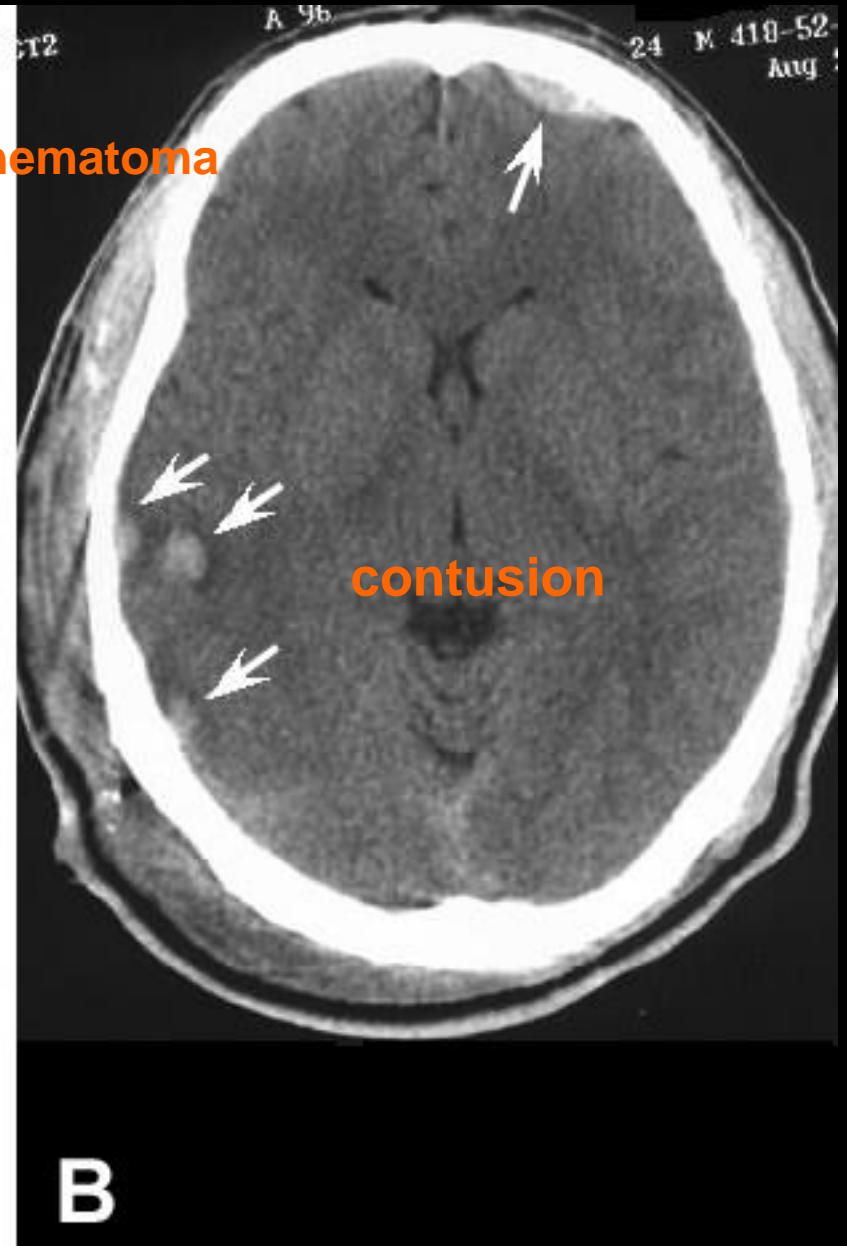
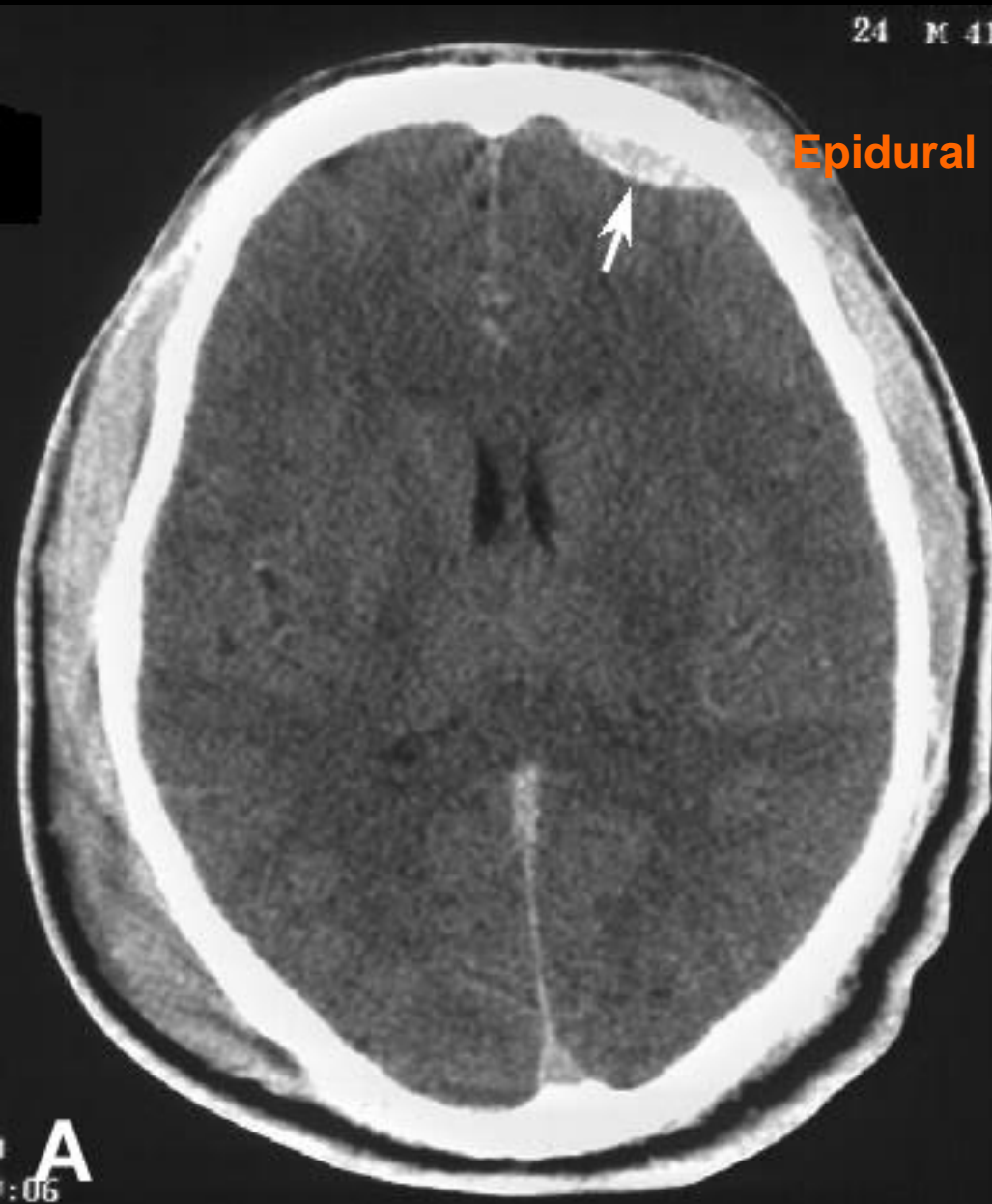NEURORADIOLOGY

- SUBDURAL HEMATOMA
 - EPIDURAL HEMATOMA
 - SUBARACHNOID HEMORRHAGE
 - **CONTUSION**
- 

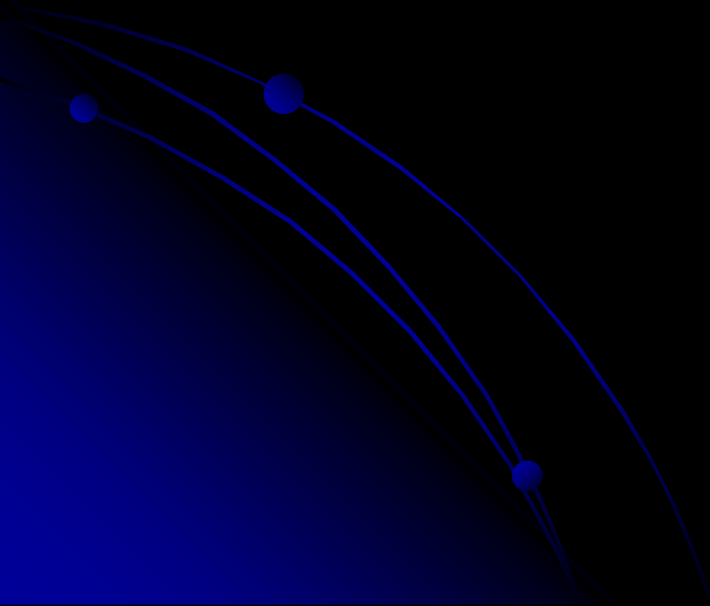


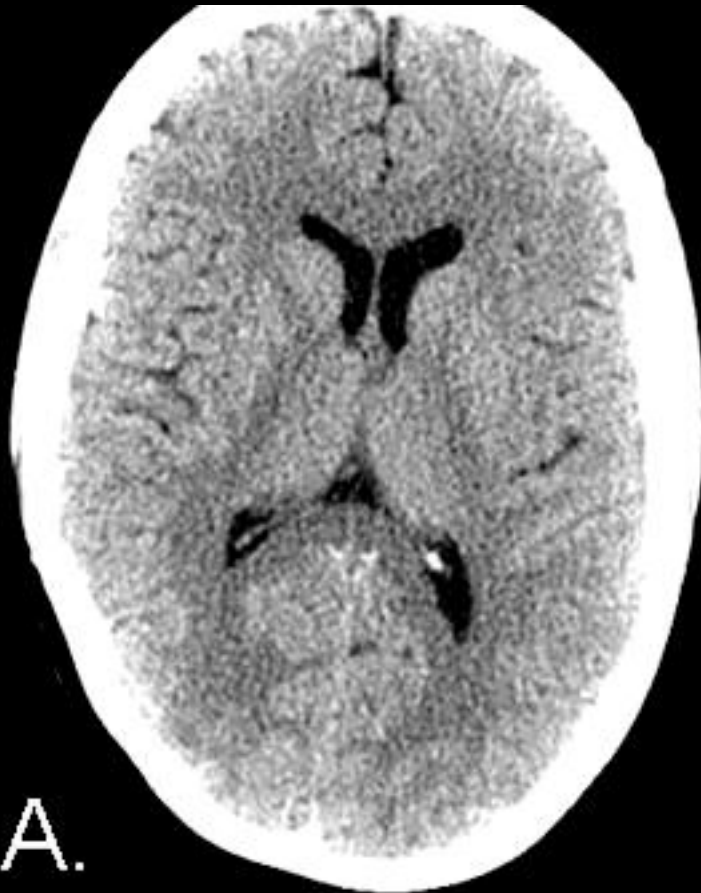Subdural hematoma

contusion



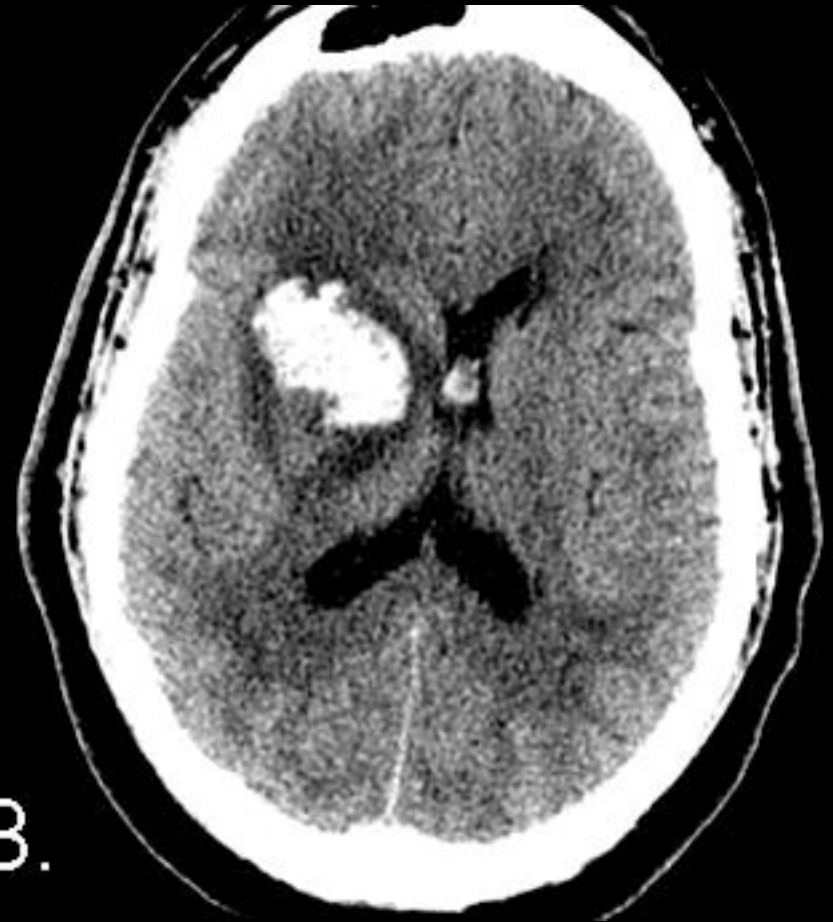NonTraumatic Emergency

- **Cerebrovascular Accident**
 - **Ask: is the stroke hemorrhagic?**
- 



A.

Normal



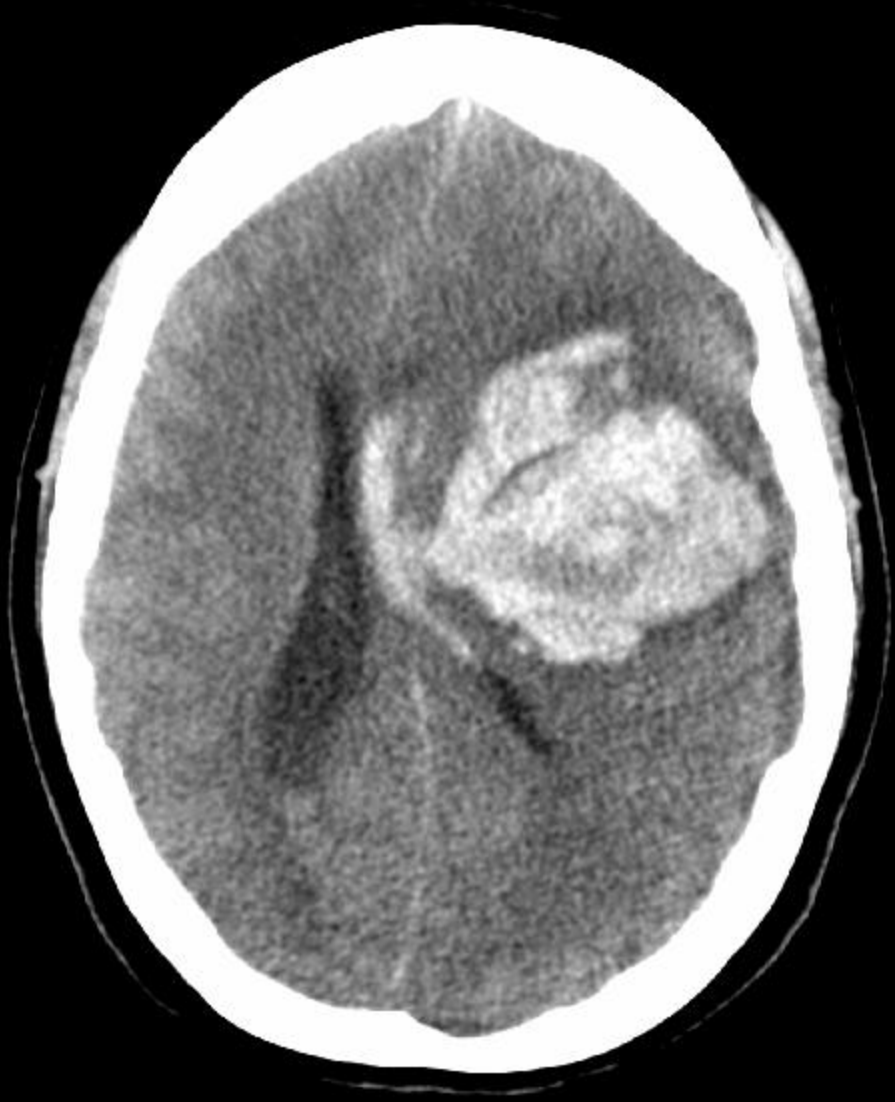B.

Acute hemorrhage right basal ganglia

SeNo: 2
ImNo: 17

x 1.467

R

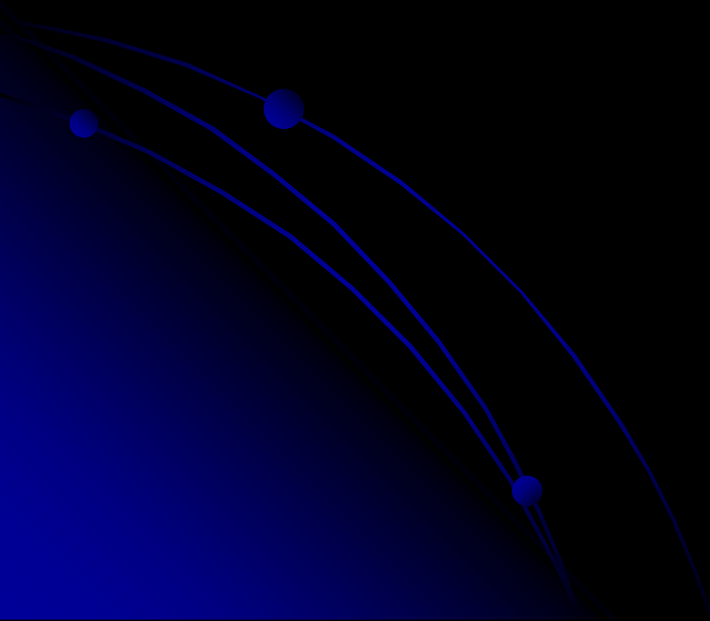


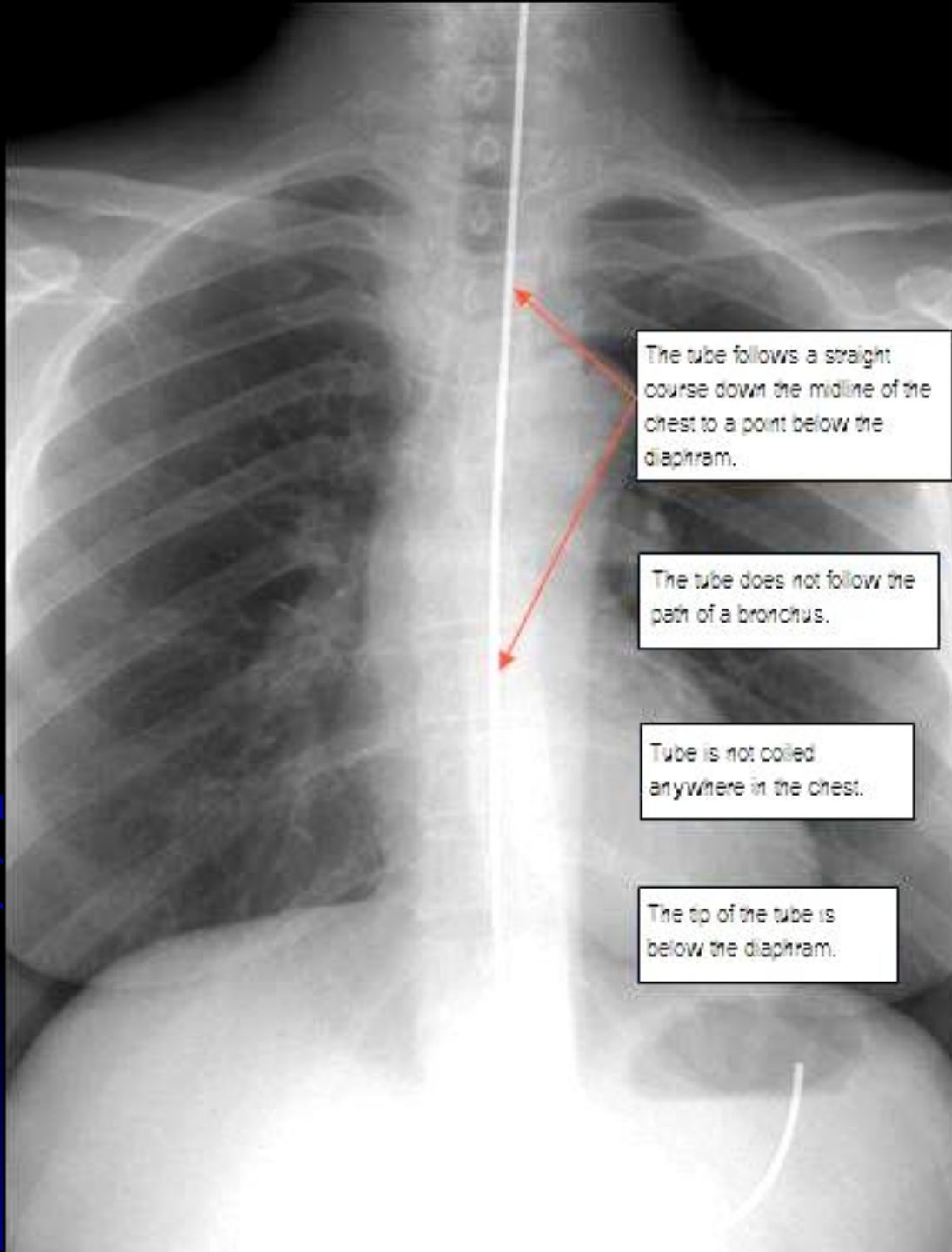
SL: 154.350
ST: 5.000
mAs: 500
kV: 120.000

NEURO REVIEW

- SUBDURAL HEMATOMA
- EPIDURAL HEMATOMA
- SUBARACHNOID HEMORRHAGE
- CONTUSION
- STROKE: hemorrhagic vs. ischemic?

TUBES, LINES, & FOREIGN BODIES





The tube follows a straight course down the midline of the chest to a point below the diaphragm.

The tube does not follow the path of a bronchus.

Tube is not coiled anywhere in the chest.

The tip of the tube is below the diaphragm.

Normal feeding tube position

SeNo:1001

ImNo:1001

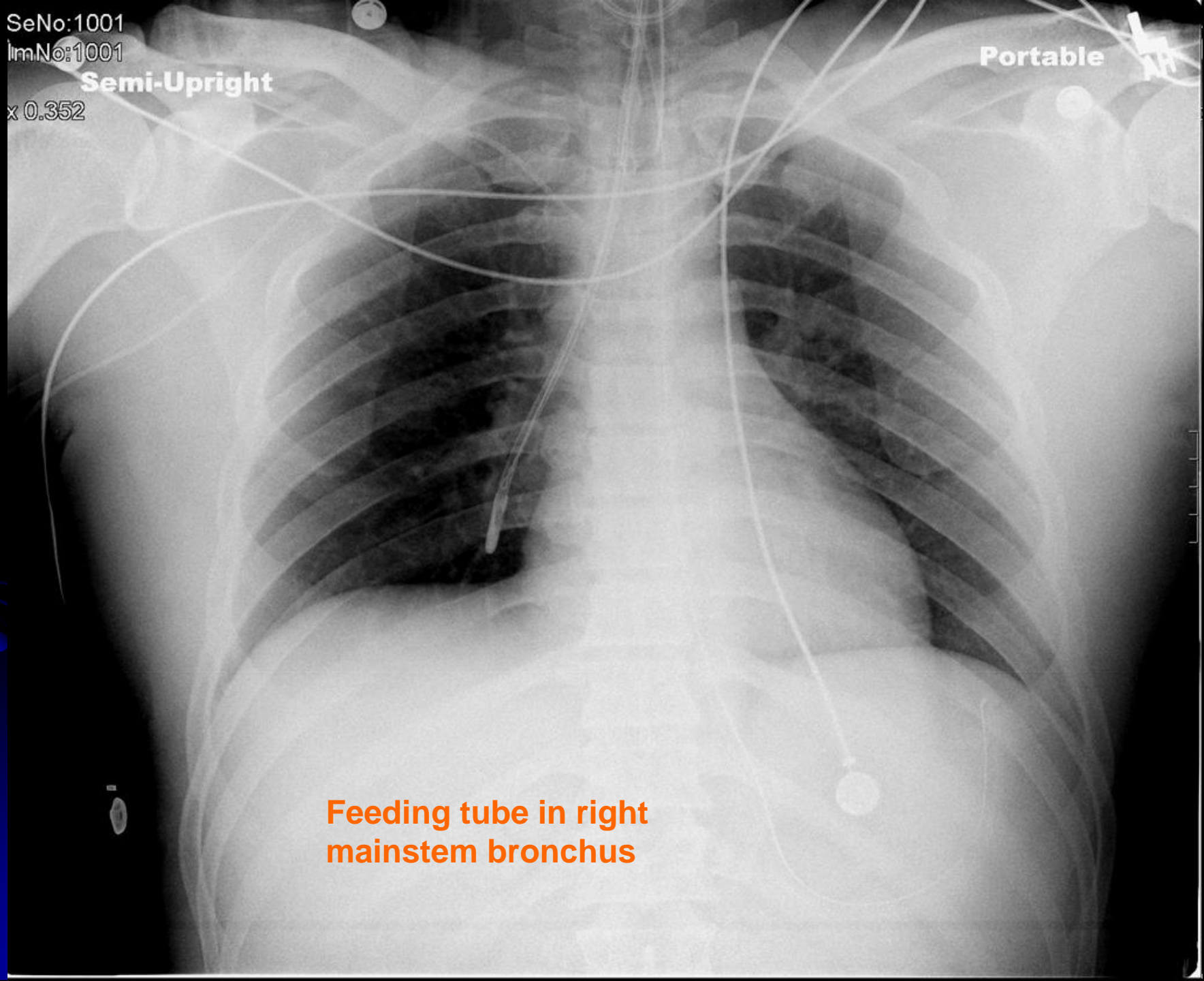
Semi-Upright

x 0.352

Portable

NR

**Feeding tube in right
mainstem bronchus**



Semi-Upright
009
12 PM R

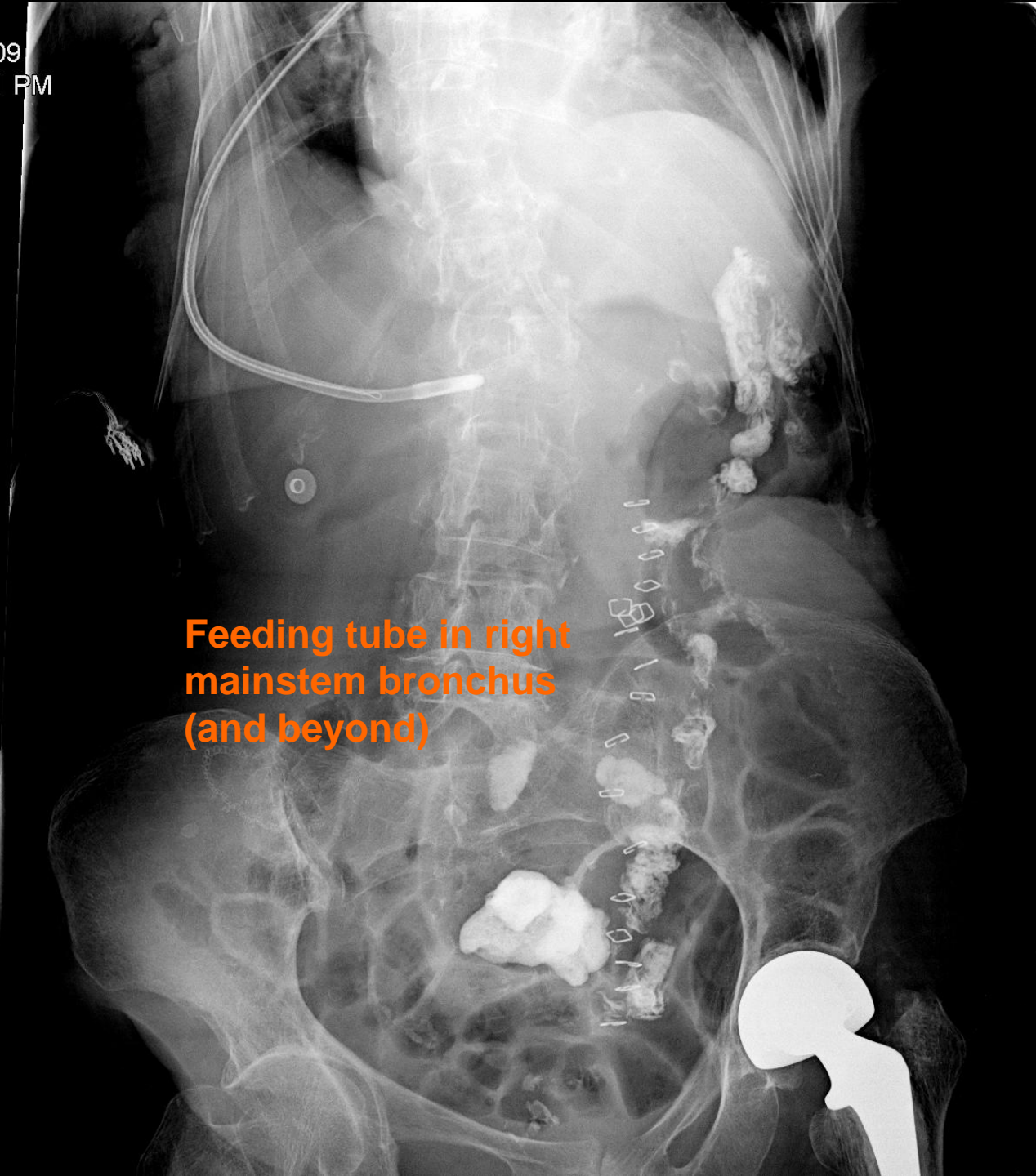
Portable

Feeding tube in right
mainstem bronchus
(and beyond)

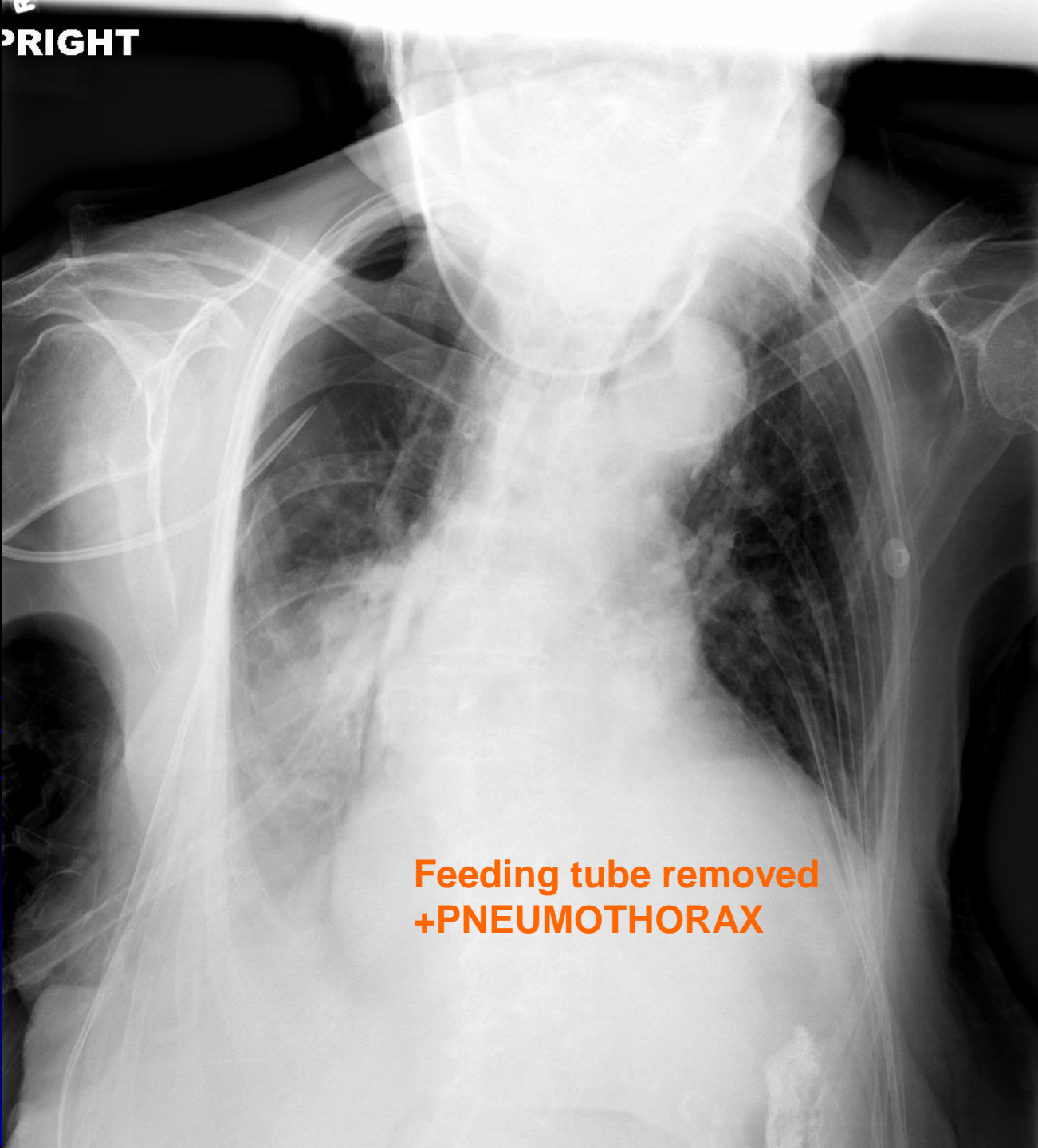

09
1 PM

**Feeding tube in right
mainstem bronchus
(and beyond)**



RIGHT



**Feeding tube removed
+PNEUMOTHORAX**



StDt:2/20/2010
StTm:6:53:07 PM

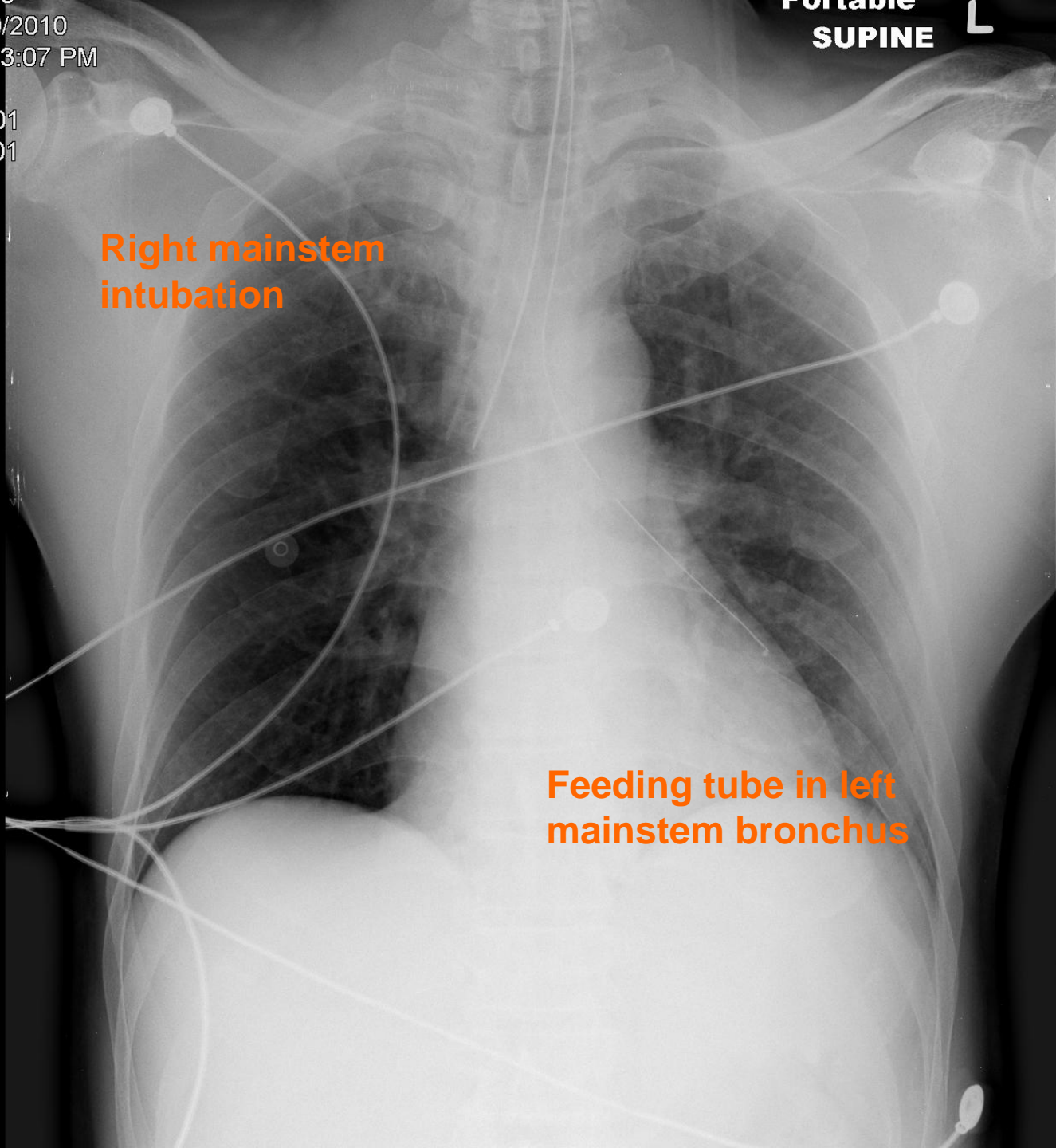
Portable
SUPINE

SeNo:1001
ImNo:1001

x 0.352

**Right mainstem
intubation**

**Feeding tube in left
mainstem bronchus**



StDt:7/10/2009
StTm:11:38:52 PM

SeNo:4
ImNo:1

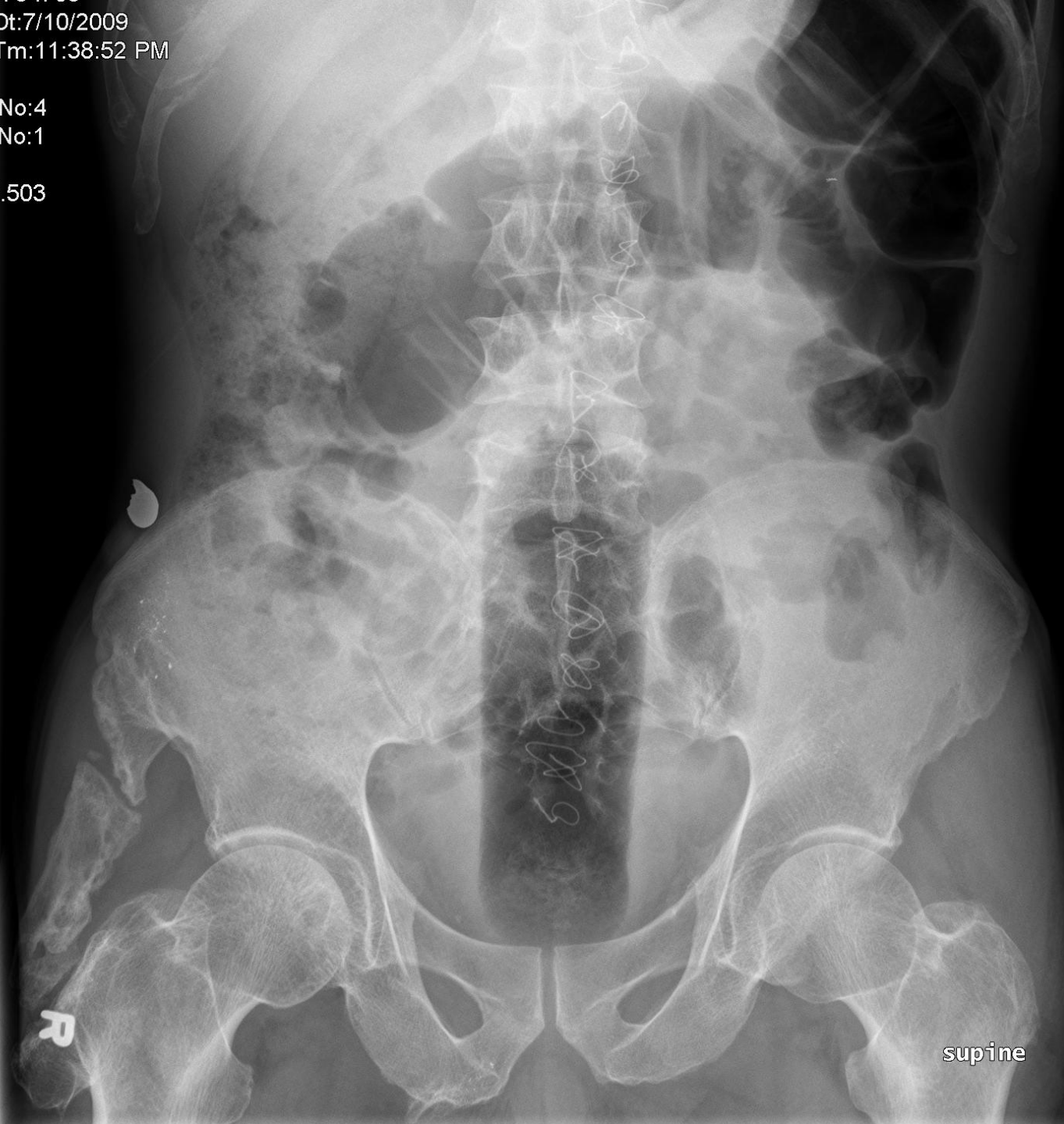x 0.503

R

R

supine

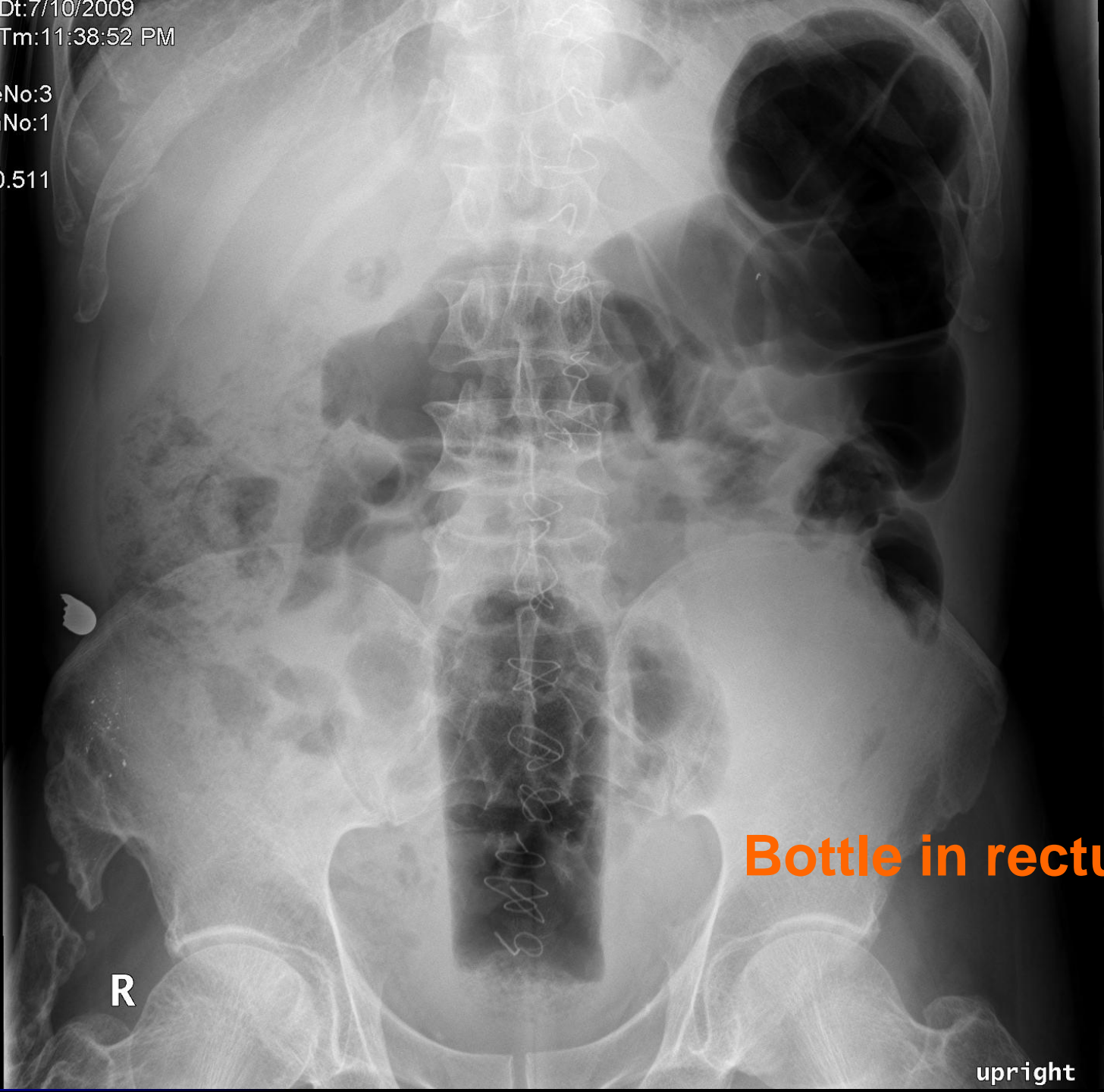
520080003



StDt:7/10/2009
StTm:11:38:52 PM

SeNo:3
ImNo:1

x 0.511



Bottle in rectum

R

upright

7:10:10204
StDt: 1/26/2010
StTm: 11:45:50 PM

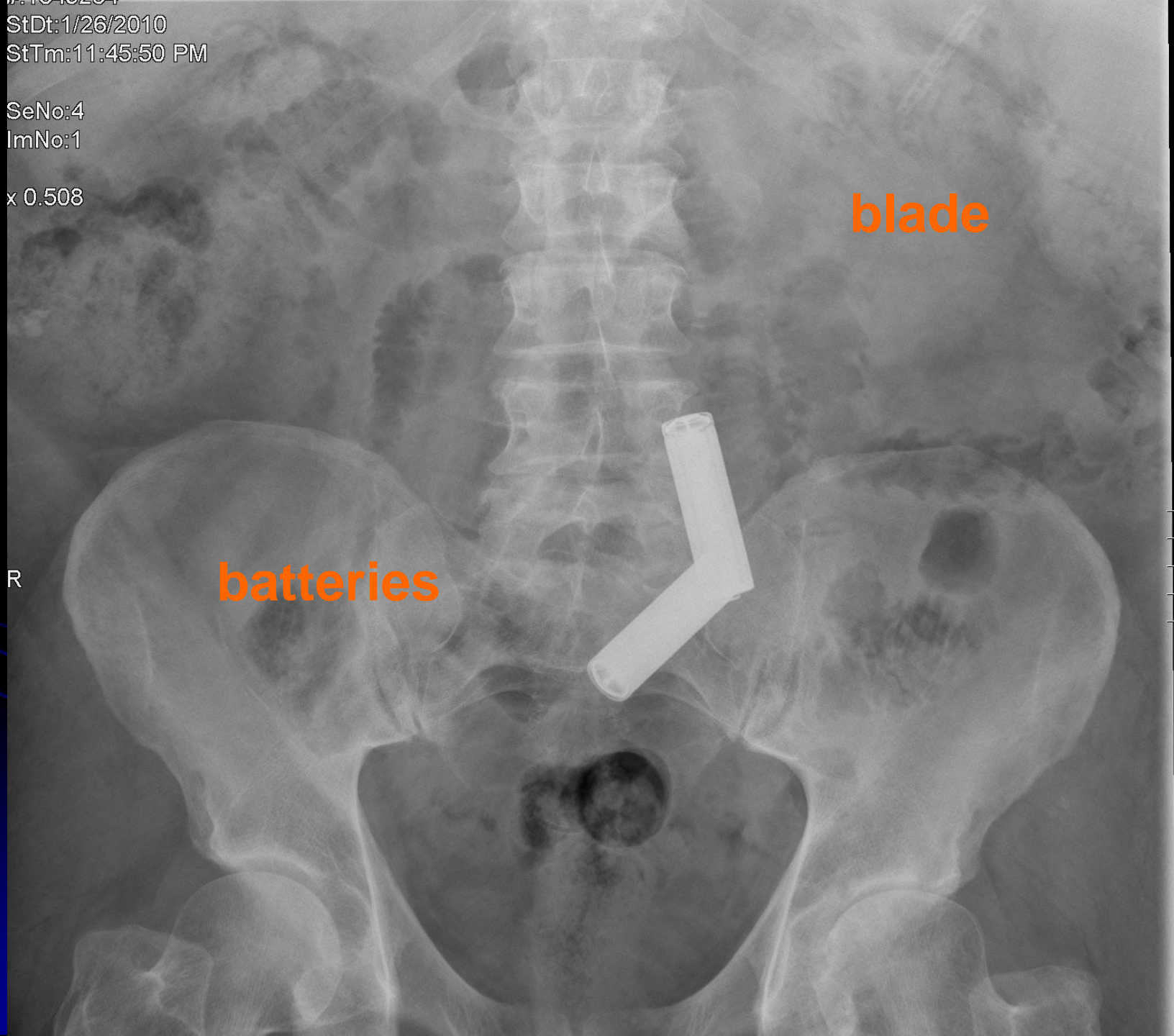
SeNo: 4
ImNo: 1

x 0.508

R

batteries

blade



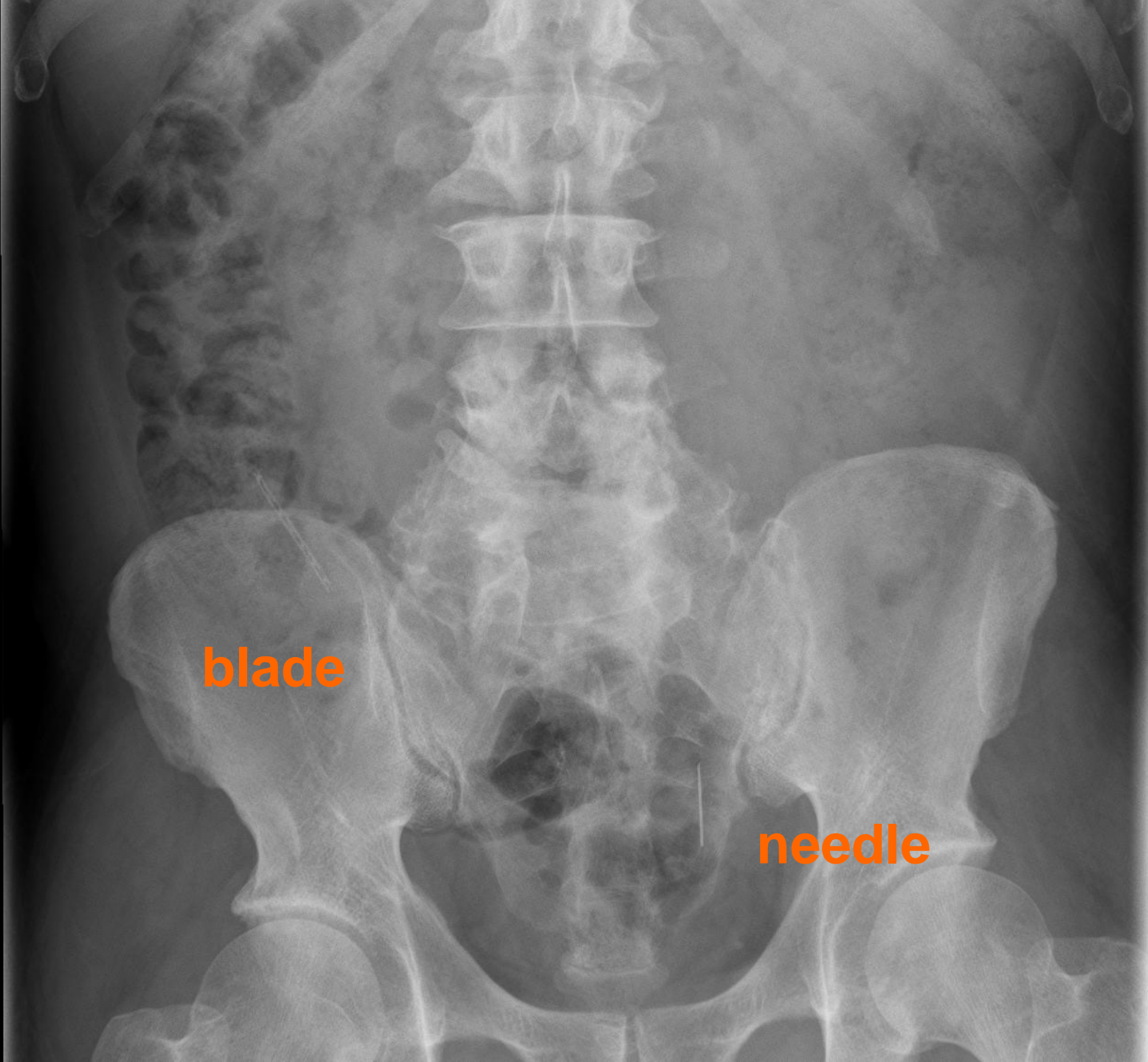
SeNo:4
ImNo:1

x 0.503

R

blade

needle

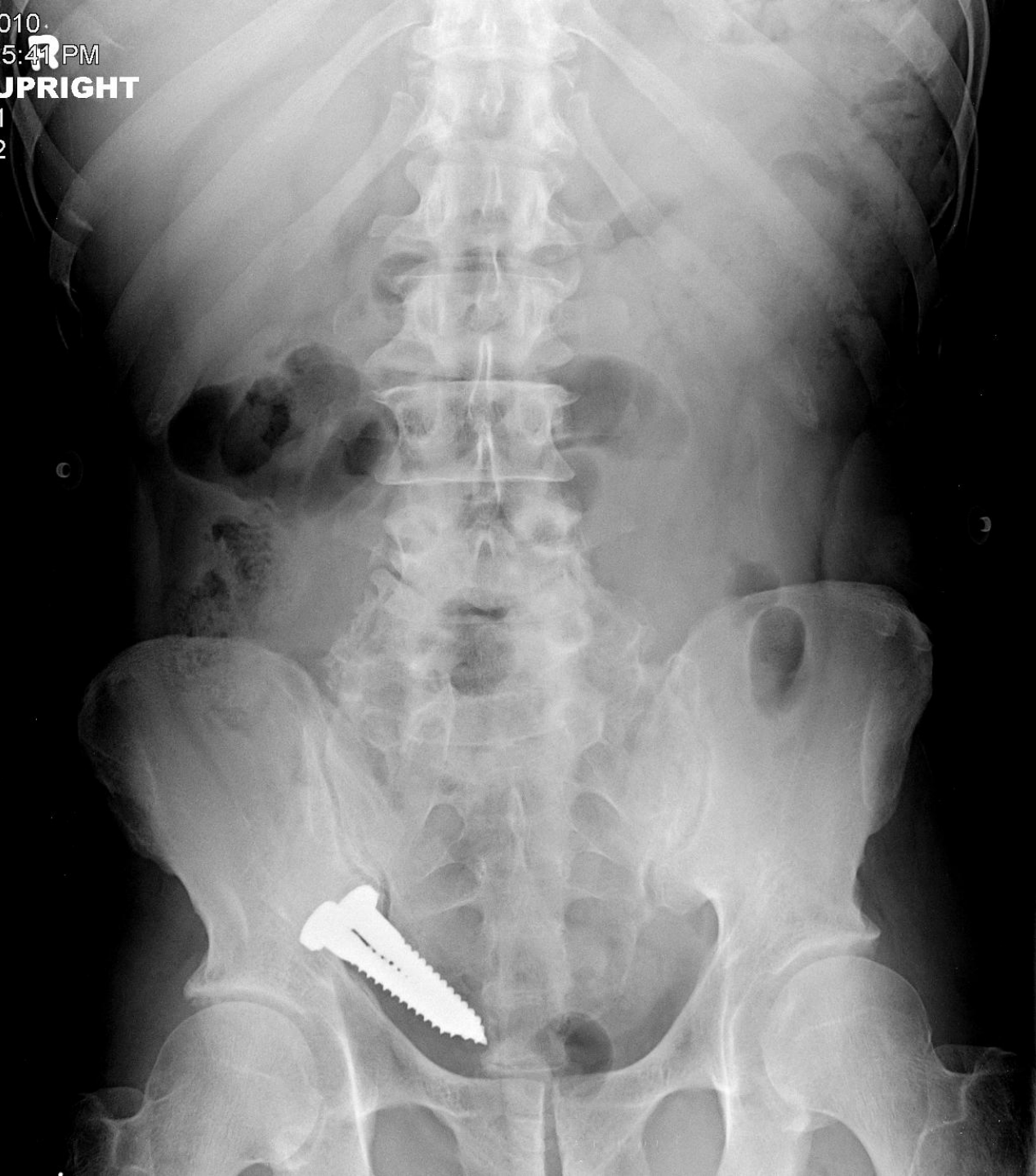

StDt: 2/2/2010
StTm: 11:25:41 PM

UPRIGHT

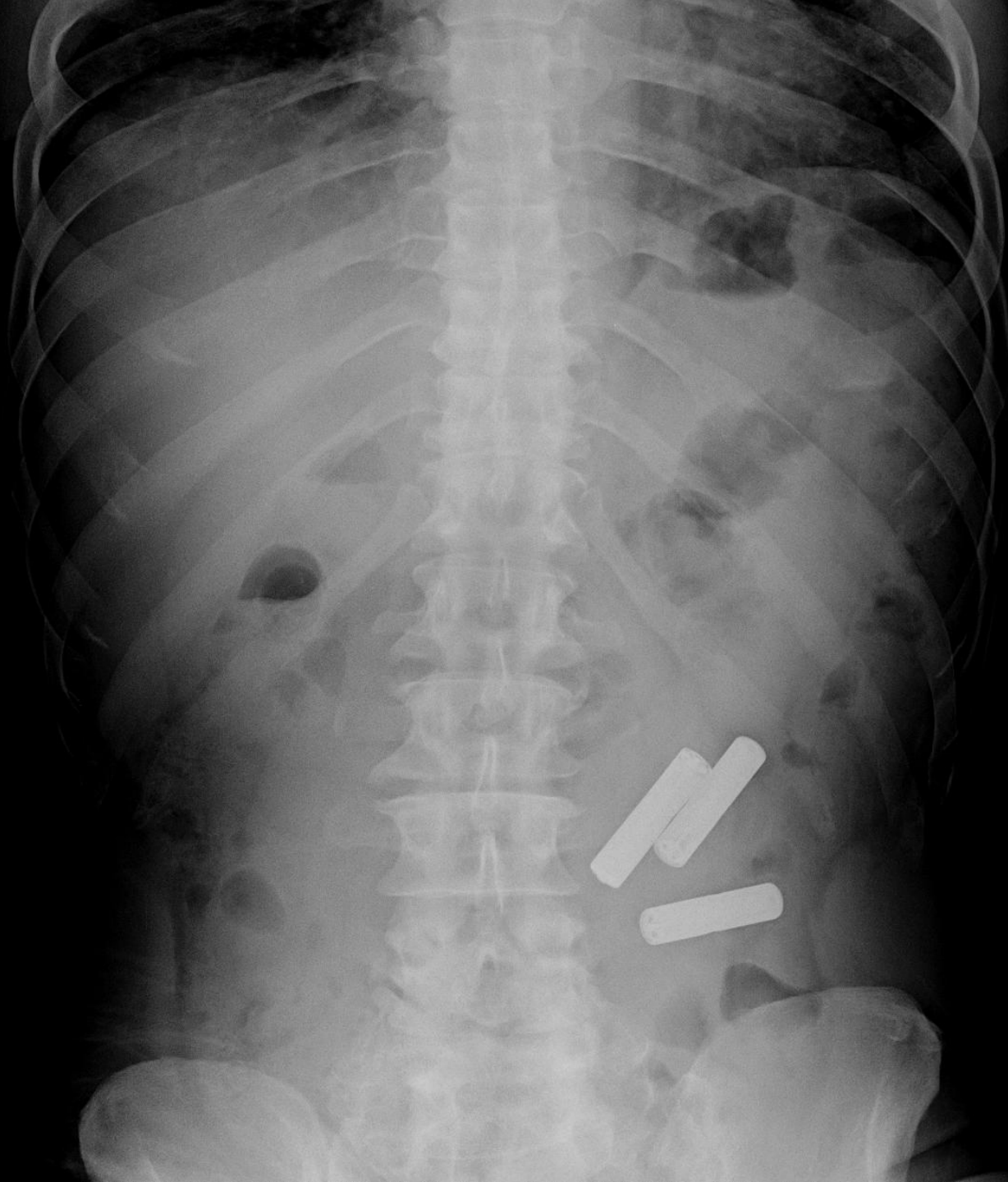
SeNo: 1001
ImNo: 1002

x 0.352



SeNo:1001
ImNo:1003

x 0.352

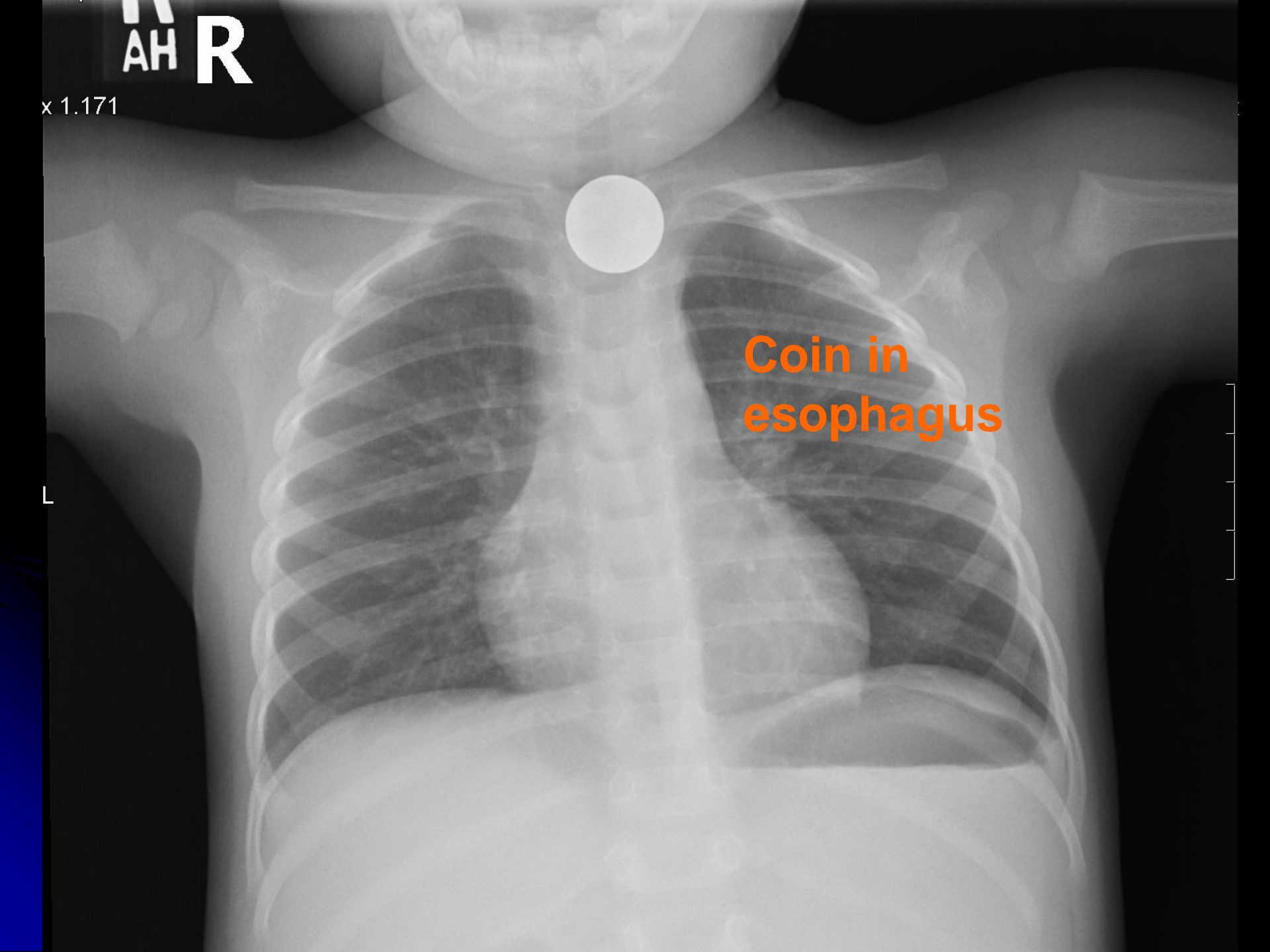


AH R

x 1.171

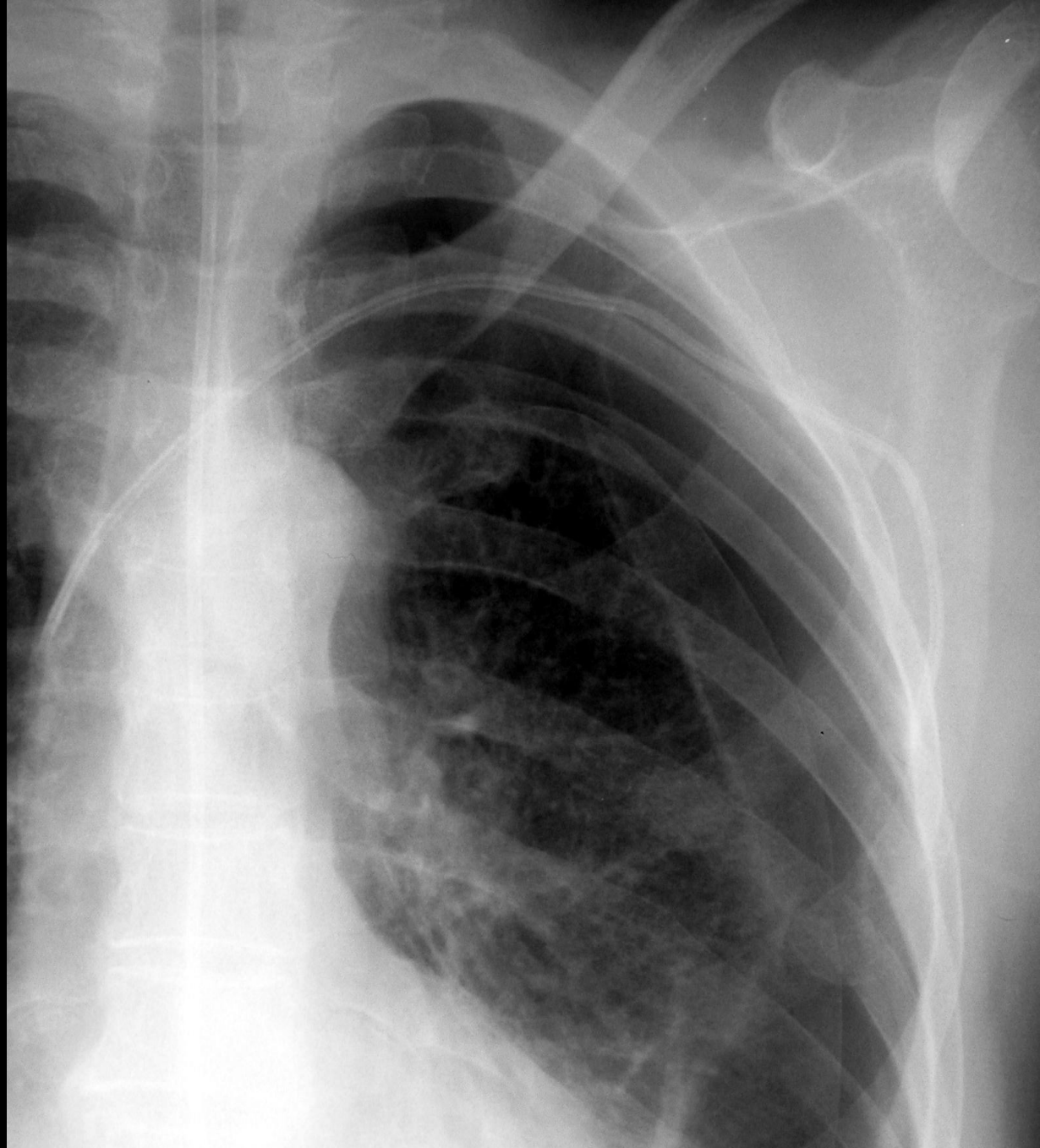
Coin in
esophagus

L




**Hx: Central
line just
placed**

+PTX



Remember:

- Tubes and lines are not benign
 - Always check placement and for possible complications
- 

THE END

